

**DESCRIPTION**

The Maryland Dermatologic Society is a professional organization of dermatologists (both in practice and in training) for the state of Maryland. Once a year, the Department of Dermatology at Johns Hopkins hosts a half a day meeting for physicians. This activity will include a plenary lecture from a national/international expert in various topics including diagnoses and management of unique dermatological conditions. Several patient cases will be presented with group-based discussion for treatment and learning purposes. This is followed by a short business meeting.

**WHO SHOULD ATTEND**

The target audience is primarily composed of practicing community and academic dermatologists, as well as dermatopathologists and residents in dermatology in the State of Maryland. In addition, the audience includes physician assistants, nurse practitioners, nurses and medical students with a special interest in dermatology.

**OBJECTIVES**

After attending this activity, the learner will demonstrate the ability to:

- Formulate a differential diagnosis for unusual or rarely encountered dermatologic findings.
- Discuss how to treat the rare manifestations of the aforementioned dermatologic conditions.
- Identify the risk factors and etiologies for dermatologic conditions, especially as related to environmental, genetic, and iatrogenic risk factors.

**ACCREDITATION STATEMENT**

This activity has been planned and implemented in accordance with the accreditation requirements and policies of the Accreditation Council for Continuing Medical Education (ACCME) through the joint providership of Johns Hopkins University School of Medicine and **Maryland Dermatologic Society**. The Johns Hopkins University School of Medicine is accredited by the ACCME to provide continuing medical education for physicians.

**CREDIT DESIGNATION STATEMENT**

The Johns Hopkins University School of Medicine designates this live activity for a maximum of 3.50 *AMA PRA Category 1 Credits™*. Physicians should claim only the credit commensurate with the extent of their participation in the activity.

**OTHER CREDITS**

American Nurses Credentialing Center (ANCC) *accepts AMA PRA Category 1 Credits™* from organizations accredited by the ACCME.

American Academy of Nurse Practitioners National Certification Program (AANP) *accepts AMA PRA Category 1 Credits™* from organizations accredited by the ACCME.

The National Commission on Certification of Physicians Assistants (NCCPA). PAs may claim a maximum of 3.50 Category 1 credits for completing this activity. NCCPA *accepts AMA PRA Category 1 Credits™* from organizations accredited by ACCME or a recognized state medical society.

**POLICY ON PRESENTER AND PROVIDER DISCLOSURE**

It is the policy of the Johns Hopkins School of Medicine that the presenter and provider globally disclose conflicts of interest. The Johns Hopkins School of Medicine OCME has established policies in place to mitigate relevant conflicts of interest prior to this educational activity. Detailed disclosure will be made prior to presentation of the education.

**NOTICE ABOUT OFF-LABEL USE PRESENTATIONS**

The Johns Hopkins School of Medicine/**Maryland Dermatologic Society Clinical Conference** may include presentations on drugs or devices, or use of drugs or devices, that have not been approved by the Food and Drug Administration (FDA) or have been approved by the FDA for specific uses only. The FDA has stated that it is the responsibility of the physician to determine the FDA clearance status of each drug or device he or she wishes to use in clinical practice.

The Johns Hopkins School of Medicine is committed to the free exchange of medical education. Inclusion of any presentation in this program, including presentations on off-label uses, does not imply an endorsement by Johns Hopkins of the uses, products, or techniques presented.

**AMERICANS WITH DISABILITIES ACT**

The Johns Hopkins School of Medicine fully complies with the legal requirements of the ADA and the rules and regulations thereof.

**COPYRIGHT INFORMATION**

All rights reserved. No part of this syllabus may be used or reproduced in any manner whatsoever without written permission except in the case of brief quotations embodied in articles or reviews.

**WHAT YOU SHOULD KNOW ABOUT GIFTS TO PHYSICIANS FROM INDUSTRY**

Gift giving from the pharmaceutical, device and medical equipment industries to physicians has long been a customary practice. But when gift giving is not practiced within established ethical boundaries, the perception of conflict of interest is raised. All physicians and physicians in training should adhere to the AMA Code of Medical Ethics, Opinion 8.061, "Gifts to Physicians from Industry" which can be found under the AMA Code of Medical Ethics at <https://code-medical-ethics.ama-assn.org/ethics-opinions/gifts-physicians-industry>.

Johns Hopkins faculty, staff, employees, students, and trainees must adhere to the more restrictive Johns Hopkins Medicine Policy on Interaction with Industry that can be found at this link <https://industryinteraction.jhu.edu/jhm-policy-on-interaction-with-industry>.

**GENERAL INFORMATION**

- **CME CREDIT FOR PHYSICIANS (MDs and DOs):** In accordance with our accreditation guidelines, we have instituted a self-reporting system for physicians to obtain *AMA PRA Category 1 Credit™*. Physicians must attest to the exact number of hours that they have been in attendance. Attestation will be required on the online post-activity evaluation.

<u>Date</u>	<u>Maximum Credit</u>
April 2, 2025	3.5

**Please Note:** Certificates for all attendees will be available upon submission of the online evaluation form that will be available to you post-activity.

- **SIGN-IN FOR ALL PARTICIPANTS:** Please be sure to sign in **once** to verify your attendance at the registration desk.
- **EVALUATIONS:** Following the activity, each attendee will be able to access the post-activity evaluation via the **My CME** section after signing in at <https://hopkinscme.cloud-cme.com>. The evaluation must be completed by **May 17, 2025** in order to receive your certificate of credit. The evaluations are most helpful to us in planning future programs, and we appreciate your comments and suggestions. We ask you to evaluate each speaker.
- **OUTCOMES SURVEY:** An outcomes survey will be sent to all physician attendees within two months post activity to assist us in determining what impact this activity had on the attendee’s practice.
- **ELECTRONIC DEVICES:** As a courtesy to speakers and other attendees, please turn off all cell phones and pagers while the meeting is in progress.

Johns Hopkins School of Medicine  
Office of Continuing Medical Education  
Turner 20, 720 Rutland Avenue  
Baltimore, Maryland 21205-2195

Telephone: (410) 502-9636  
Fax: (866) 510-7088  
Website: <https://hopkinscme.cloud-cme.com>

Johns Hopkins University General Counsel

Email CME: [cmenet@jhmi.edu](mailto:cmenet@jhmi.edu)  
(410) 502-2843

Johns Hopkins Health System General Counsel

(410) 955-7949  
(410) 955-6070 Urgent Only

**CONFIDENTIALITY DISCLAIMER FOR CME CONFERENCE PARTICIPANTS**

I certify that I am participating in a Johns Hopkins University School of Medicine CME activity for accredited training and/or educational purposes.

I understand that while I am participating in this capacity, I may be exposed to "protected health information," as that term is defined and used in Hopkins policies and in the federal HIPAA privacy regulations (the "Privacy Regulations"). Protected health information is information about a person's health or treatment that identifies the person.

I pledge and agree to use and disclose any of this protected health information only for the training and/or educational purposes of my visit and to keep the information confidential. I agree not to post or discuss this protected health information, including pictures and/or videos, on any social media site (e.g. Facebook, Twitter, etc.), in any electronic messaging program or through any portable electronic device.

I understand that I may direct to the Johns Hopkins Privacy Office any questions I have about my obligations under this Confidentiality Pledge or under any of the Hopkins policies and procedures and applicable laws and regulations related to confidentiality. The contact information is: Johns Hopkins Privacy Office, telephone: 410-614-9900, e-mail: HIPAA@jhmi.edu.

---

"The Office of Continuing Medical Education at the Johns Hopkins University School of Medicine, as provider of this activity, has relayed information with the CME participants and certifies that the visitor is attending for training, education and/or observation purposes only."

For CME Questions, please contact the CME Office  
(410) 955-2959 or e-mail [cmenet@jhmi.edu](mailto:cmenet@jhmi.edu).  
For CME Certificates, please call (410) 502-9636.

Johns Hopkins University  
School of Medicine Office of Continuing Medical  
Education Turner 20/720 Rutland Avenue  
Baltimore, Maryland 21205-2195

Reviewed & Approved by:  
General Counsel, Johns Hopkins Medicine (4/1/03)  
(Updated 4/09, 3/14, 9/16 and 9/22/20)

## FULL DISCLOSURE POLICY AFFECTING CME ACTIVITIES

As a provider approved by the Accreditation Council for Continuing Medical Education (ACCME), Johns Hopkins University School of Medicine Office of Continuing Medical Education (OCME) requires attested and signed global disclosure of the existence of all financial interests or relationships with ineligible companies from any individual in a position to control the content of a CME activity sponsored by OCME.

The following relationships have been reported for this activity:

NAME	ROLE	RELATIONSHIPS
<u>Jeffrey S. Dover, MD, FRCPC</u>	Presenter	<b>Grant or Research Support:</b> <b>Abbvie</b> ; Cutera; Fount; Revance; Solta; Teoxane <b>Executive:</b> Controversies and Conversations; SkinCare Physicians
<u>Sewon Kang, MD</u>	Planner	<b>Membership on Advisory Committees or Review Panels, Board Membership, etc.:</b> Allergan; CeraVe; Eli Lilly and Co.; Galderma <b>Grant or Research Support:</b> AmorePacific <b>Advisor:</b> Estee Lauder; Incyte
<u>Andrew Tadros, MD, PhD</u>	Presenter	<b>Consulting Fee:</b> Aldena Therapeutics; Alys Pharmaceuticals; Vimela Therapeutics <b>Ownership, including stock or stock option ownership in privately held companies:</b> Aldena Therapeutics; Alys Pharmaceuticals; Vimela Pharmaceuticals

**No one else in a position to control the content of this educational activity has disclosed a relevant financial interest or relationship with ineligible companies. All relevant conflicts of interest have been mitigated prior to the commencement of the activity.**

Note: Grants to investigators at the Johns Hopkins University are negotiated and administered by the institution which receives the grants, typically through the Office of Research Administration. Individual investigators who participate in the sponsored project(s) are not directly compensated by the sponsor, but may receive salary or other support from the institution to support their effort on the project(s).

## Jeffrey S. Dover, M.D., FRCPC



Dr. Dover was born in Brooklyn and raised in Ottawa, Canada where his extended family still resides. He is proud of his two daughters, Sophie and Isabel, and his wife Tania who also practices Dermatology at SkinCare Physicians in Boston. Dr. Dover graduated as the silver medalist, *magna cum laude* with an M. D. degree from the University of Ottawa. His dermatology training was received at the University of Toronto followed by research fellowships at St. John's Hospital for Diseases of the Skin at the University of London in London, England, and a two-year photomedicine fellowship at the Beth Israel Hospital and the Massachusetts General Hospital of Harvard Medical School. Dr. Dover is a former Associate Professor of Dermatology at Harvard Medical School, was Chief of Dermatology at the New England Deaconess Hospital for over ten years and also Associate Chairman of Dermatology at Beth Israel Deaconess Medical Center. He is Associate Clinical

Professor of Dermatology, at Yale University School of Medicine, and Associate Professor of Dermatology at Brown Medical School. A Boston dermatologist, and Co-director of SkinCare Physicians, Dr. Dover's research interests are lasers in medicine, cosmetic surgery and medical education.

Dr. Dover is the author of over 550 scientific publications. He has co-authored and edited over 55 textbooks, several with SkinCare Physicians colleagues. Titles include *Illustrated Cutaneous Laser Surgery: A Practitioner's Guide*, *Controversies and Conversations in Cutaneous Laser Surgery*, *Atlas of Cosmetic Surgery*, *Pocket Guide to Cutaneous Medicine and Surgery*, *Cutaneous Medicine and Surgery: Self-Assessment and Review*, and the bestselling book series, *Procedures in Cosmetic Dermatology* with books on various titles including *Botulinum Toxin*, *Soft Tissue Augmentation*, *Lasers, Lights and Energy Sources*, *Liposuction*, *Hair Transplantation*, *Blepharoplasty*, *Face Lifting*, *Skin Tightening*, *Scar Management*, *Body Contouring*, *Cosmeceuticals*, and *Leg Veins*. These texts, many of which are going into their 5<sup>th</sup> editions, have been translated into many different languages including French, Italian, Spanish, Russian, Polish and Chinese and are sold to physicians all over the world. Dr. Dover has also co-authored three books for lay individuals; *Skin Deep: An A-Z of Skin Disorders, Treatments and Health*, *the Encyclopedia of Skin and Skin Disorder*, and the *Youth Equation*. Dr. Dover was the founding editor of *Journal Watch for Dermatology*, produced by the publishers of the *New England Journal of Medicine*.

Dr. Dover is Past President of the American Society of Dermatologic Surgery, the American Society for Lasers in Medicine and Surgery, and the New England Dermatological Society. He has organized and directed numerous medical conferences including *Controversies in Cutaneous Laser and Cosmetic Surgery* with Dr. Arndt.

Dr. Dover has received many honors including listings in the *Who's Who of American Medicine*, *Who's Who in America*, *Guide to Top Doctors*, *Woodward and White's The Best Doctors in America*, and repeated nominations for the Teacher of The Year Award at Harvard Medical School. He has been honored with the Leon Goldman Award, the Ellet Drake award, and the Caroline and William Mark Memorial Award of the American Society for Laser Medicine and Surgery and he was honored for his work in laser surgery by the Sturge Weber Foundation at its 20<sup>th</sup> Annual Gala. In 2024 Dr. Dover received the American Academic Dermatology Surgery Society Elizabeth McBurney Award for Clinical Excellence.

**ACTIVITY DIRECTOR**

**Farah Succaria, MD**  
Assistant Professor  
Department of Dermatology  
Johns Hopkins University School of Medicine

**GUEST FACULTY**

**Jeffrey S. Dover, MD, FRCPC**  
SkinCare Physicians

**JOHNS HOPKINS FACULTY**

**Leora Aizman, MD**  
Resident Physician

**Eugene Brooks, MD**  
Resident Physician

**Austin Burns, MD**  
Resident Physician

**Justin Choi, MD**  
Resident Physician

**Jaclyn Daigneault, MD**  
Resident Physician

**Ista Egbeto, MD**  
Resident Physician

**Ramie Fathy, MD**  
Resident Physician

**Breanna Nguyen, MD**  
Resident Physician

**Connie Qiu, MD, PhD**  
Resident Physician

**Michelle Robinson, MD**  
Resident Physician

**Sophie Roh, MD**  
Resident Physician

**Autumn Saizan, MD**  
Resident Physician

**Varsha Simha, MD**  
Resident Physician

**Srona Sengupta, MD, PhD**  
Resident Physician

**Andrew Tadros, MD, PhD**  
Resident Physician

**Saimanoja Talluru, MD**  
Resident Physician

**Raghav Tripathi, MD, MPH**  
Resident Physician

**Jerry Tsai, MD, MHP**  
Resident Physician

**David Weiner, MD, MBE**  
Resident Physician

**Katherine Whang-Rice, MD**  
Resident Physician

**Suzanne Xu, MD**  
Resident Physician



**PROGRAM**

*This session is not eligible for AMA PRA Category 1 Credit™.*

12:30 – 1:00

**Patient Viewing** (Virtual)

1:00 – 2:00

**Guest Speaker**

Jeffrey S. Dover, MD, FRCPC, SkinCare Physicians

**Enhancing the Patient Experience**

**Case Presentations**

2:00 – 2:07

**PTEN Hamartoma Tumor Syndrome**

Austin Burns, MD

2:07 – 2:14

**PERP-related Erythrokeratoderma**

Sophie Roh, MD

2:14 – 2:21

**Granulomatous Lymphoplasmacytic Plaque**

Leora Aizman, MD

2:21 – 2:28

**Periorbital Sweet Syndrome**

Jaclyn Daigneault, MD

2:28 – 2:35

**Parry-Romberg Syndrome**

Ramie Fathy, MD

2:35 – 2:42

**Pigmented Oncholemmoma**

Katherine Whang-Rice, MD

2:42 – 2:49

**Eccrine Spiradenoma**

Connie Qiu, MD, PhD

2:49 – 2:56

**Angiosarcoma in the Setting of Stewart-Treves Syndrome**

Eugene Brooks, MD

2:56 – 3:03

**Primary Cutaneous EBV+ Diffuse Large B-Cell Lymphoma**

Ista Egbeto, MD

3:03 – 3:10

**Birt-Hogg Dube Syndrome**

Andrew Tadros, MD, PhD

3:10 – 3:17

**Pseudomyogenic Hemangioendothelioma**

Andrew Tadros, MD, PhD

3:17 – 3:24

**Eruptive Acral AIMPs in an Immunosuppressed Patient**

Varsha Simha, MD

- 3:24 – 3:31      **Cutaneous Atypical Mycobacteria Infection with a Molluscoid Clinical Presentation**  
Michelle Robinson, MD
- 3:31 – 3:38      **VZV Granulomatous Dermatitis**  
Breanna Nguyen, MD
- 3:38 – 3:45      **Immunotherapy-induced Erosive Lichen Sclerosus**  
Raghav Tripathi, MD, MPH
- 3:45 – 3:52      **Blaschkoid Discoid Lupus Erythematosus**  
Jerry Tsai, MD, MPH
- 3:52 – 3:59      **Generalized Morphea and Eosinophilic Fasciitis**  
Autumn Saizan, MD
- 3:59 – 4:06      **Pustular IgA Vasculitis**  
Justin Choi, MD
- 4:06 – 4:13      **Bullous Lupus in Childhood**  
Suzanne Xu, MD
- 4:13 – 4:20      **Cutaneous Crohns Disease**  
David Weiner, MD, MBE
- 4:20 – 4:27      **Wong Type Dermatomyositis**  
Sai Talluru, MD
- 4:27 – 4:34      **Epidermolysis Bullosa Simplex**  
Srona Sengupta, MD, PhD
- 4:34 – 5:04      *This session is not eligible for AMA PRA Category 1 Credit™.*  
**Business Meeting**

Adjourn

You will receive an email notification to complete the evaluation form and to attest to the number of hours in attendance.

**The Johns Hopkins School of Medicine and the Maryland Dermatologic Society take responsibility for the content, quality and scientific integrity of this CME activity.**

**The schedule is subject to change.**





## CASE #1

### Authors

Austin Burns, MD  
Jihad Alhariri, MD

### History

Our patient is a 31 y.o. female with PMHx of papillary thyroid cancer and Stage IIIa metastatic breast cancer who was initially diagnosed with *PTEN* genetic mutation at age 19. She initially presented to dermatology at age 27 for full body skin exam, with nevus sebaceous of the scalp noted at that time. Biopsies of multiple other lesions were taken and consistent fatty hypertrophy/macrodactyly of the right fourth toe, multiple xanthogranulomas, as well as superficial spreading melanoma. Patient continued to follow up with dermatology over several years, with interval development of gingival hyperplasia, verrucae plana (in area of prior radiation therapy) as well as verrucous keratoses. She then developed a growing ovoid yellowish papule, of the right abdomen, with biopsy consistent with lipidized fibrous histiocytoma. It has been proposed that this patient's *PTEN* mutation has been a significant factor in the development of these multiple skin growths.

### Physical Examination

At time of initial presentation, there was a well circumscribed circular plaque on the scalp vertex with overlying thick scale as well as multiple circular papules some with yellowish hue/others with pink hue on the upper and lower extremities, a dark brown macule on right medial calf, and a large nodule on distal 4th digit of right foot. Patient subsequently developed multiple warty, skin-colored papules as well.

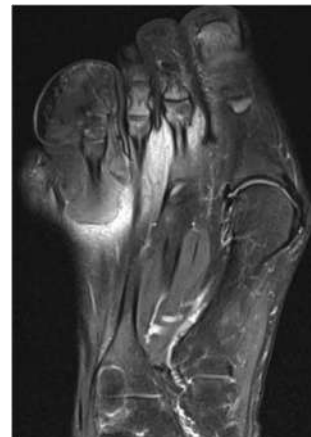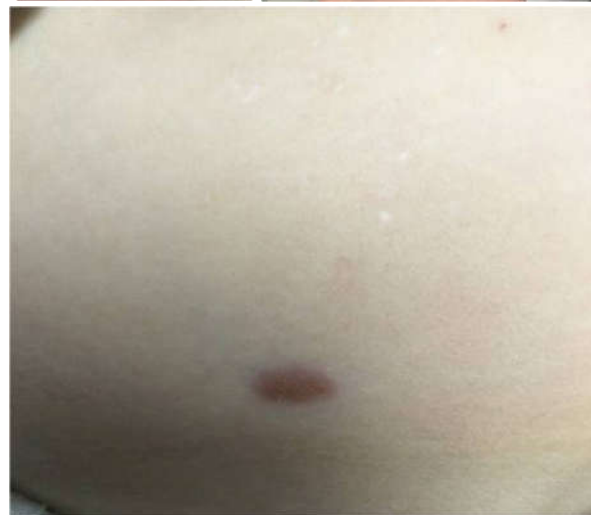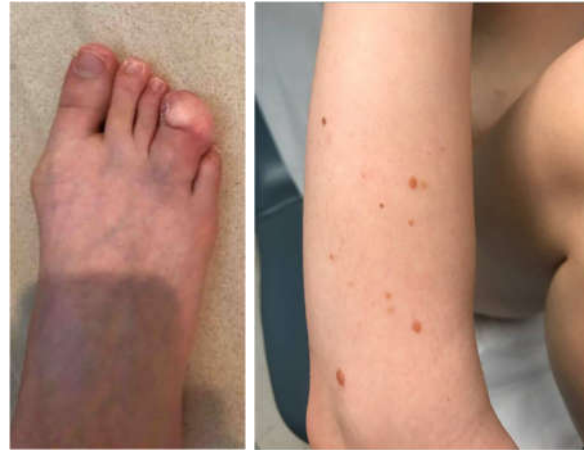### Imaging

MRI 4/12/2021, right lower leg/foot: fatty hypertrophy/macrodactyly of the right fourth toe

Biopsy results as detailed in above history.

### Treatment

Malignant melanoma was excised and lipidized fibrous histiocytoma was removed with excisional biopsy. Right fourth toe macrodactyly was found to be inoperable.



## ***PTEN* Hamartoma Tumor Syndrome**

---

*PTEN* hamartoma tumor syndrome (PHTS) encompasses multiple conditions, including Cowden syndrome, Bannayan-Riley-Ruvalcaba syndrome, *PTEN*-related Proteus syndrome, and *PTEN*-related Proteus-like syndrome. Each of these conditions may demonstrate characteristic dermatologic findings, so it is important for dermatologists to be able to identify these conditions to ensure proper counseling is provided to affected patients.

Cowden syndrome (CS) is a multiple hamartoma syndrome that is classically associated with trichilemmomas and papillomatous papules, in addition to macrocephaly. Patients with CS are also at increased risk for several malignancies, including breast cancer (lifetime risk 85%), thyroid cancer (35%), renal cell cancer (34%), and endometrial cancer (28%). There are pathognomonic, major, and minor criteria used for the clinical diagnosis of this condition, with the notable dermatologic criteria including facial trichilemmomas, acral keratoses, papillomatous lesions, and mucosal lesions.

Bannayan-Riley-Ruvalcaba syndrome (BRRS) classically demonstrates pigmented macules of the genitals (especially the glans penis) in addition to macrocephaly, lipomas, and hamartomatous polyposis.

*PTEN*-related Proteus syndrome (PPS) involves various congenital malformations and hamartomatous overgrowth of tissues, which may present with epidermal nevi, connective tissue nevi, and hyperostosis.

All patients who are suspected of having PHTS should be referred to genetics for additional testing, as diagnosis requires molecular genetic testing for a pathogenic *PTEN* variant. Online scoring systems may also be helpful for identifying at-risk patients and further specifying the PHTS subtype an individual patient may have. Other conditions that may be considered in the differential diagnosis of this syndrome are *AKT1*-related Proteus syndrome, Juvenile polyposis syndrome, Birt-Hogg-Dubé syndrome, Neurofibromatosis type 1, Nevoid basal cell carcinoma syndrome, and Peutz-Jeghers syndrome.

Due to the elevated risk of malignancy, patients should undergo routine tumor surveillance, including yearly thyroid ultrasound and skin check starting at time of diagnosis. Women should begin yearly breast screening and monthly self-exams starting at age 30 and consider transvaginal ultrasound/endometrial biopsy at age 35. Colonoscopy is also recommended starting at age 35 but should be tailored based on individual risk and findings. Specific cancer screenings based on family history should also be started 5-10 years prior to the youngest age of family member diagnosis.

Treatment of benign and malignant lesions of PHTS is the same as for non-syndromic variants. Topical 5-fluorouracil and ablative therapies (eg. curettage, cryosurgery, laser) can be used for management of mucocutaneous lesions that are symptomatic. Cutaneous lesions should only be excised if malignancy is suspected or if symptoms are significant, but do not need to be prophylactically removed if these findings are not present.

---

### **References**

Black J, Coffin CM, Dehner LP. Fibrohistiocytic tumors and related neoplasms in children and adolescents. *Pediatric and Developmental Pathology*. 2012;15(SUPPL. 1):181-210. doi:10.2350/11-03-1001-PB.1

Yehia L, Eng C. *PTEN* Hamartoma Tumor Syndrome Summary Diagnosis Suggestive Findings.

*GeneReviews*. Published online 2021:1-25.

[https://www.ncbi.nlm.nih.gov/books/NBK1488/pdf/Bookshelf\\_NBK1488.pdf](https://www.ncbi.nlm.nih.gov/books/NBK1488/pdf/Bookshelf_NBK1488.pdf)

## CASE #2

### Authors

Youkyung Sophie Roh, M.D.,  
Jihad M. Alhariri, M.D.

### History

Our patient is a 21-year-old Hispanic man who presented to our clinic for evaluation of a chronic generalized rash and palmoplantar thickening. As an infant through his teens, he was previously followed by Johns Hopkins pediatric dermatology, but had been lost to follow-up. Patient was born at term, and first developed wrinkling and redness of the skin around 4 months of age, and later developed generalized thickening of the skin including the palms and soles by about 1 year of age. As a child, he had been diagnosed with: hereditary acanthosis nigricans, eczema, psoriasis, and chronic tinea corporis. He had trialed numerous topical regimen (steroids, tacrolimus, ammonium lactate, salicylic acid, tretinoin, ketoconazole); oral clindamycin and dapsone; phototherapy; methotrexate; long-term oral terbinafine; and etanercept. He had 2 prior biopsies which were nonspecific. He had had numerous skin swabs positive for *T. rubrum*. Previous genetic mutation screen for FGFR3 was negative. At time of presentation, he was flaring in the setting of being off all therapy for several years.

### Physical Examination

There are erythematous scaly thin plaques on face, trunk and upper extremities. There is diffuse leathery skin and accentuated skin lines. There is extensive hyperkeratosis on bilateral plantar and palmar surfaces. There is total dystrophy of all toenails.

### Laboratory Data

Numerous skin swabs positive for *T. rubrum*.

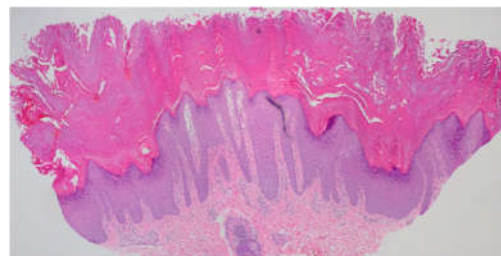
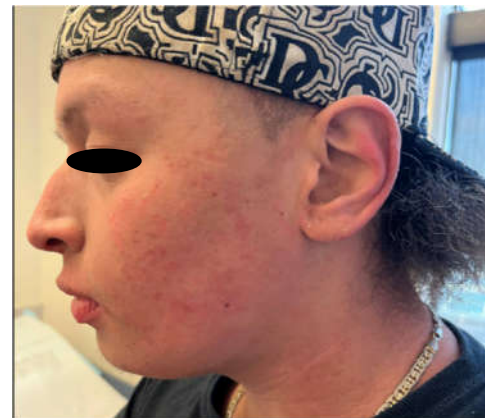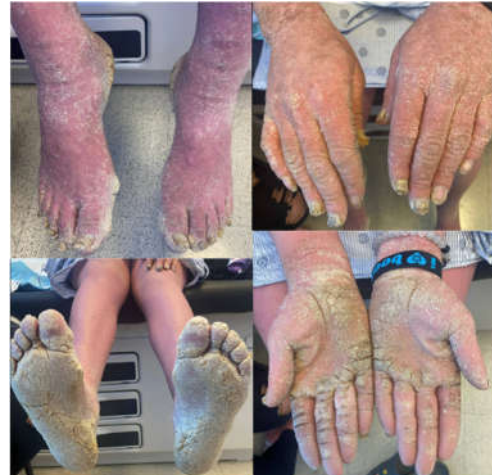GeneDx PPK & Congenital Ichthyosis Panel: positive for homozygous autosomal recessive variant of *PERP* gene.

### Histopathology

**(5/4/23, left distal forearm):** The biopsy shows dermatophytosis, hyperkeratosis and verrucous epidermal hyperplasia.

### Treatment

Patient was referred to genetics (as noted). He was started on acitretin and emollients. Plan is to obtain cytokine panel in order to determine next best step.



## ***PERP*-related Erythrokeratoderma**

---

Erythrokeratoderma (EK) is a heterogeneous group of disorders of defective keratinization characterized by variable degrees of excessive scaling and ichthyosis leading to well-circumscribed erythrokeratotic plaques symmetrically distributed on the trunk, extremities, and/or face, as well as palmoplantar keratoderma (PPK). Some entities may also be associated with hair abnormalities and cardiomyopathy. Various genes have been linked to erythrokeratoderma, including but not limited to: *TPRV3*, *GJB3*, *GJB4*, *GJA1*, *KRT83*, *TRPM4*, *LOR*, *DSP*, *ABHD5*, *KDSR*, *DSG1*, *DSG2*, *PKP1*, and *JUP*.

Recently, case reports of EK related to the *PERP* gene nonsense and frameshift mutations have been described in literature. Specifically, both autosomal dominant and autosomal recessive forms have been reported. Clinical presentations include generalized ichthyosis within the first weeks of life, thickened hyperkeratosis of palms and soles, varying degrees of hair and nail dystrophy, psoriasiform dermatitis, and recurrent cutaneous yeast, fungal, or dermatophyte infections., which were all characteristics seen in our patient. Such phenotypic constellation can lead to diagnostic challenges, as patients are often initially diagnosed with alternate diagnoses including guttate psoriasis or pustular psoriasis.

While the exact pathophysiology of *PERP*-related EK is unknown, the *PERP* gene encodes a tetraspan plasma membrane transcription factor that is activated by both p53 and p63, which functions as both an apoptosis mediator and component of desmosomes and other cell junctions. It is expressed in stratified, simple, columnar, complex and transitional epithelia, as well as in various tumors and cardiomyocytes. Disease-varying variants likely result in immature desmosomes, reduced cell-cell adhesion in response to mechanical stress and hyperproliferation of the epidermis. As *PERP*-related EK is very rare with a limited number of reported cases, the prevalence is unknown. There is also a lack of established treatments, but mostly focus on symptomatic improvements with the use of emollients, keratolytics, topical steroids, and possibly topical and oral retinoids. More research is needed on the efficacy of biologics on the treatment of *PERP*-related EK.

---

### **References**

Duchatelet S, Boyden LM, Ishida-Yamamoto A, Zhou J, Guibbal L, Hu R, Lim YH, Bole-Feysot C, Nitschké P, Santos-Simarro F, de Lucas R, Milstone LM, Gildenstern V, Helfrich YR, Attardi LD, Lifton RP, Choate KA, Hovnanian A. Mutations in *PERP* Cause Dominant and Recessive Keratoderma. *J Invest Dermatol*. 2019 Feb;139(2):380-390. doi: 10.1016/j.jid.2018.08.026. Epub 2018 Oct 12. PMID: 30321533; PMCID: PMC6586468.

Patel N, Alkeraye S, Alobeid E, Alshidi T, Helaby R, Abdulwahab F, Shamseldin HE, Alkuraya FS. Confirming the recessive inheritance of *PERP*-related erythrokeratoderma. *Clin Genet*. 2020 Apr;97(4):661-665. doi: 10.1111/cge.13699. Epub 2020 Jan 12. PMID: 31898316.

Youssefian L, Khodavaisy S, Khosravi-Bachehmir F, Park JS, Saeidian AH, Mahmoudi H, Saffarian Z, Naraghi ZS, Kamyab-Hesari K, Zeinali S, Vahidnezhad H, Uitto J. Ichthyosis, psoriasiform dermatitis, and recurrent fungal infections in patients with biallelic mutations in *PERP*. *J Eur Acad Dermatol Venereol*. 2022 Mar;36(3):472-479. doi: 10.1111/jdv.17856. Epub 2021 Dec 29. PMID: 34863005.



## CASE # 3

### Authors

Srona Sengupta, M.D., Ph.D.  
Daniel Synkowski, M.D.

### History

Our patient is a 16-year-old Caucasian female with a medical history notable for anxiety (on Effexor) who initially presented with a history of blisters on the body since birth. Parents recounted examples of blisters on the body induced by trauma: a) when removing band-aid after receiving newborn vaccines; b) at diaper pressure lines; c) on arms/knees when crawling. When older, the patient developed blisters on the feet (walking), mouth (dental procedures, biting inside of cheek), buttocks (too tight underwear), face (pimples). Denied nail changes. While she had no blisters at the first visit, she then presented in 07/2024 with several bullae on the feet in the setting of increased physical activity/crawling (she played a woodland creature at a play). Family history negative for blistering in the parents or brother. She was seen at UMD in 2018 and biopsy was obtained. She was given a diagnosis but parents did not recall what it was and were unable to obtain records.

### Physical Examination

On the foot pad, lateral aspect, and heel of the left plantar foot, there were 2-3 cm tense bullae; on the right plantar foot pad and toes, there were hyperpigmented patches at sites of prior blisters, with one small tense blister at lateral 5<sup>th</sup> toe digit.

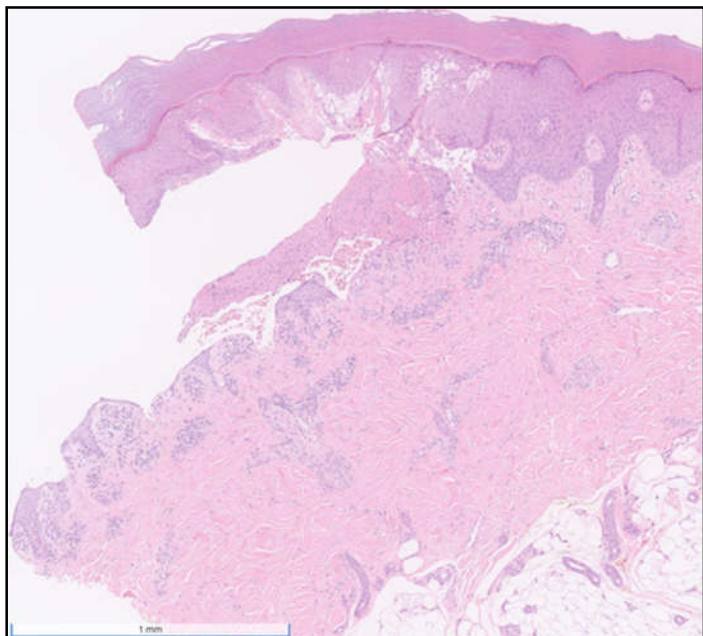
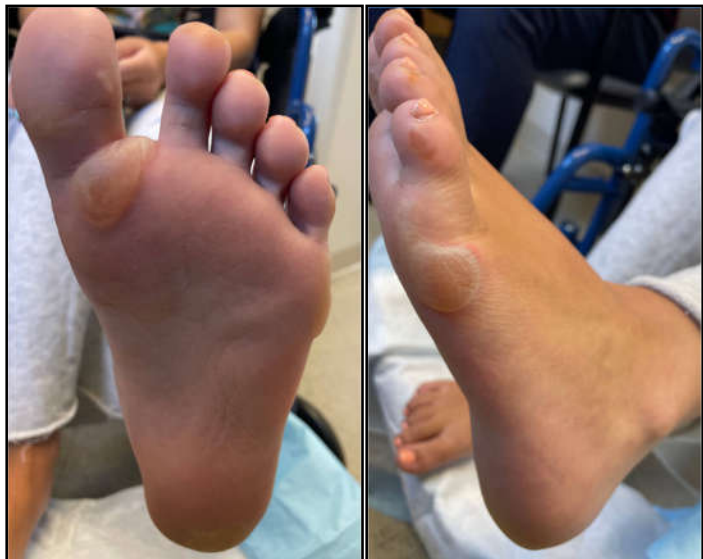### Laboratory Data - None

### Histopathology

Biopsy from the left lateral foot subepidermal split concerning for either EB simplex or a friction blister. DIF was negative.

### Treatment

She was assessed by JH Genetics. Evaluation revealed a heterozygous known pathogenic mutation in *KRT5*, consistent with EBS. She was provided with wound care supplies, mupirocin for open wounds, recommended to continue lifestyle changes to support minimal mechanical trauma, and referred to Pediatric Dermatology for further management.



4X

## Epidermolysis Bullosa Simplex

---

Epidermolysis bullosa simplex (EBS) is characterized by fragility of the skin and mucosa resulting in non-scarring blisters and erosions caused by minor mechanical trauma. The severity of blistering can be localized, typically to the hands/feet, or widespread. Other cutaneous features include keratoderma of the palms and soles, nail dystrophy, milia, and hyper- and/or hypopigmentation. Rarely, grouped or herpetiform blisters can be seen in severe EBS.

EBS is caused by mutations in structural proteins of the epidermis (EBS), dermal-epidermal junction (junctional EB) or in the papillary dermis (dystrophic EB). Most cases of EBS are due to autosomal dominant (AD) mutations in genes encoding Keratins 5 and 14. Unlike junctional and dystrophic EB, which are more commonly associated with extracutaneous manifestations, only a few forms of EBS have been associated with such manifestations including: pyloric atresia (autosomal recessive mutation in plectin and  $\alpha 6\beta 4$  integrin), cardiomyopathy (AD mutation in Kelch-like protein 24), and nephropathy (AR mutation in CD151).

EBS should be suspected in patients with chronic early-onset mechano-bullous disease. Biopsy of the blister site and perilesional skin for DIF should be done to assess for pauci-cellularity of the blister and to rule out immune-mediated bullous conditions, in which the DIF should be negative. Referral to Genetics can assess whether the patient has a pathogenic variant in known EB genes. Alternatively, immunofluorescence antigen mapping or transmission electron microscopy of biopsy specimens from a freshly induced blister can be done to determine the plane of cleavage and to assess for the expression/distribution of basement membrane proteins.

Treatment involves avoidance of mechanical trauma, wound care, and infection prevention. Pharmacologic treatments are limited. Sulforaphane can induce homologous keratins (i.e. Keratin 16/17) and reduce blistering in preclinical models of EBS (Keratin 14-null mice). Studies to identify such treatments for EBS due to Keratin 5 mutations are needed, as in the case profiled here.

---

### References

- Bolognia, J. L., Schaffer, J. V., & Cerroni, L. (Eds.). (2024). *Dermatology* (5th ed.). Elsevier.
- Coulombe PA and Lee C-H. Defining keratin protein function in skin epithelia: Epidermolysis Bullosa Simplex and its aftermath. *J Invest Dermatol.* 2012 Jan 26; 132(302):763-775.
- Hamada et al., Novel keratin 5 and 14 gene mutations in patients with epidermolysis bullosa simplex from Poland, *Arch Dermatol Res* (2005) 296: 577-579.
- Kerns ML et al., Reprogramming of Keratin Biosynthesis by Sulforaphane Restores Skin integrity in Epidermolysis Bullosa Simplex. *PNAS.* 2007 Sep 4;104(36):14460-5.
- Sorensen CB et al., Identification of novel and known mutations in the genes for keratin 5 and 14 in Danish patients with epidermolysis bullosa simplex: correlation between genotype and phenotype, *J. Invest Dermatol.* 1999 Feb; 112(2): 184-90.
- Vellarikkal SK et al., Exome sequencing reveals a novel mutation, p.L325H, in the KRT5 gene associated with autosomal dominant Epidermolysis Bullosa Simplex Koebner type in a large family from western India, *Hum Genome Var.* 2014 Sep 4: 1: 14007.
- Wertheim-Tysarowska K et al., Novel sporadic and recurrent mutations in KRT5 and KRT14 genes in Polish epidermolysis bullosa simplex patients: further insights into epidemiology and genotype-phenotype correlation, *J. Appl Genet.*, 2016 May; 57 (2): 175-81.

**CASE #4****Authors**

Ramie Fathy, MD

**History**

Our patient is a 13-year-old male who initially presented at the age of 8 with concerns for a facial bump and skin discoloration that had been progressing for approximately three years. His mother first noticed a "dent" on his forehead, which subsequently extended to involve his scalp, left cheek, nostril, and jawline. More recently, his father noted that the left side of his nose and chin appeared smaller. The patient reported no pain or tenderness associated with these changes and had not tried any treatments. He denied any vision issues, seizures, or headaches. He was noted to be a top honor student and followed regularly with a dentist. Initial evaluation led to the initiation of treatment with prednisone and methotrexate.

**Physical Examination**

There is a linear band of sclerotic atrophic hyperpigmented plaques extending from the left frontal scalp to the left forehead and then onto the left cheek and chin. The affected scalp is without hair growth. Left-sided hemifacial atrophy with asymmetry of the left nostril, left nasal ala, and left chin is present. Erythema noted over the left aspect of the face that improved with treatment. There is a significant deviation and abnormality in the left-sided jaw and tooth placement. Increased overlying soft tissue of bilateral knees without effusion is noted.

**Laboratory Data**

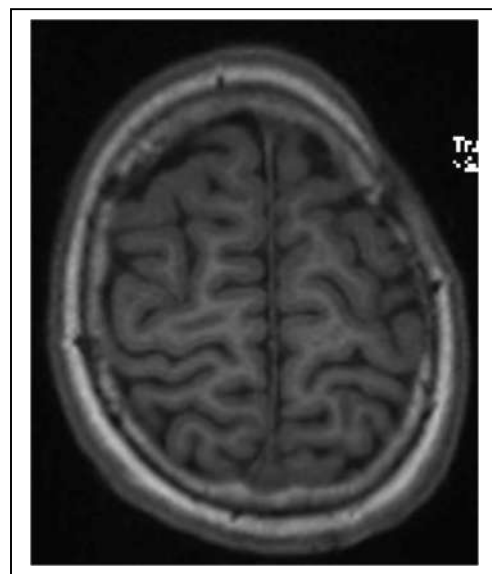
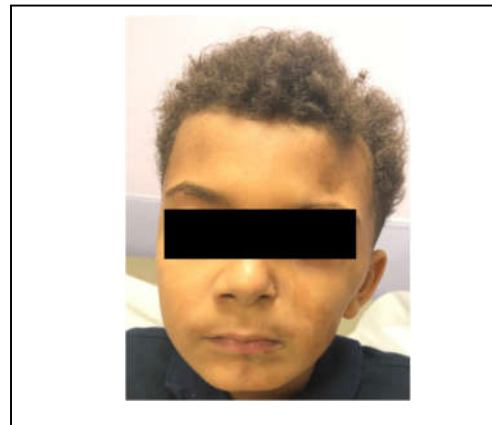None.

**Radiologic Data**

10/29/2019 MRI brain w/wo contrast showed thinning/atrophy of the left fronto-parietal scalp and underlying parietal bone, consistent with en coup de sabre. No abnormal signal intensity or enhancement involving the brain parenchyma was noted. Atrophy of the left facial soft tissues was also observed (11/2019). Repeat MRI in 12/2023 was stable.

**Treatment**

The patient was initially treated with oral prednisone and methotrexate starting in October 2019. Prednisone was tapered off by April 2020. Methotrexate was discontinued in 2021 due to intolerance. In December 2023, treatment was restarted with oral methotrexate, which was later switched to subcutaneous methotrexate at a dose of 25 mg weekly. The patient is also on folic acid supplementation. A long prednisone taper was initiated in January 2024 and completed. He is also taking calcium and vitamin D gummies and famotidine. The patient is under the care of pediatric dermatology, rheumatology, neurology, and is attempting to establish care with a craniofacial dental specialist.



## A Case of Parry-Romberg Syndrome

---

Linear morphea, also known as localized scleroderma, is an inflammatory condition that affects the skin and underlying tissues.<sup>1</sup> The “en coup de sabre” variant is characterized by a linear scar on the forehead resembling a saber cut.<sup>2</sup> Parry-Romberg syndrome (PRS) is a rare form of linear morphea associated with progressive atrophy of one side of the face, an atrophy that can involve the skin, subcutaneous fat, muscle, and sometimes bone.<sup>2</sup> The diagnosis is primarily clinical, based on the characteristic facial findings, although ancillary tests such as magnetic resonance imaging (MRI) may be used to evaluate for intracranial involvement in some cases.<sup>2</sup> In many patients, laboratory tests—including autoantibody panels—are largely unremarkable and are used mainly to exclude other connective tissue diseases.<sup>1</sup>

Treatment for linear morphea and PRS is directed at halting disease progression and managing symptoms. Immunosuppressive medications, particularly methotrexate and corticosteroids, are commonly used to control the inflammatory process.<sup>3</sup> Once the disease has stabilized, surgical and cosmetic procedures such as fat grafting or the use of fillers may be considered to address any residual cosmetic disfigurement.<sup>4</sup> The prognosis is variable, as the disease typically stabilizes after several years; however, the resulting cosmetic changes can be permanent.<sup>1</sup> Because the etiology of PRS remains unknown and no clear genetic inheritance has been identified, it is considered a sporadic condition.<sup>2</sup> For optimal long-term outcomes, regular follow-up with a multidisciplinary team—including dermatologists, rheumatologists, neurologists, ophthalmologists, and dentists—is crucial.<sup>2,4</sup>

---

### References

Papara C, De Luca DA, Bieber K, *et al*. Morphea: The 2023 update. *Front Med*. 2023;10:1108623. doi:10.3389/fmed.2023.1108623

Tollefson MM, Witman PM. En coup de sabre morphea and Parry-Romberg syndrome: a retrospective review of 54 patients. *J Am Acad Dermatol*. 2007;56(2):257-263. doi:10.1016/j.jaad.2006.10.959

Torok KS, Arkachaisri T. Methotrexate and corticosteroids in the treatment of localized scleroderma: a standardized prospective longitudinal single-center study. *J Rheumatol*. 2012;39(2):286-294. doi:10.3899/jrheum.110210

Werth VP. Morphea Treatment & Management. *Medscape Reference*. Updated February 24, 2025. Accessed March 24, 2025. <https://emedicine.medscape.com/article/1065782-treatment>

## CASE #5

### Authors

Katherine Rice, MD  
Myriam Gonzalez, MD MPH

### History

Our patient is an 84-year-old African-American woman with PMH including HTN, peripheral neuropathy, diabetes and chronic kidney disease who presents for years of abnormal left great toenail growth with increasing pain of the toe and new onset drainage of white fluid.

### Physical Examination

The left great toe shows significant dystrophic hyperkeratotic overgrowth of entire nail bed with prominent dark discoloration most prominent along the medial aspect of the lesion extending onto proximal and medial nail folds.

### Laboratory Data

None

### Radiologic Data

**2/2024 XR Left toe:** No acute osseous abnormalities. Radiopacity centered adjacent to the hallux nail bed.

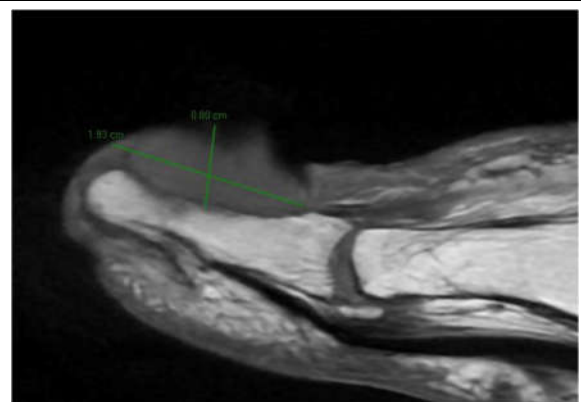
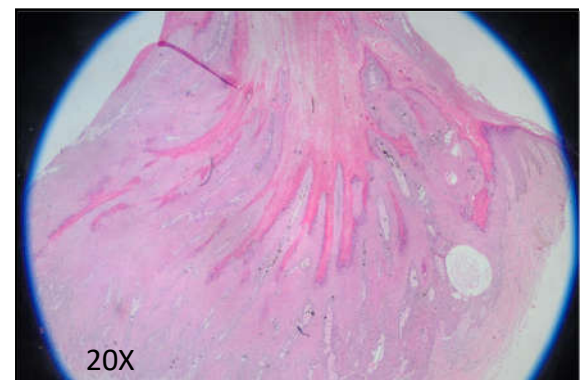
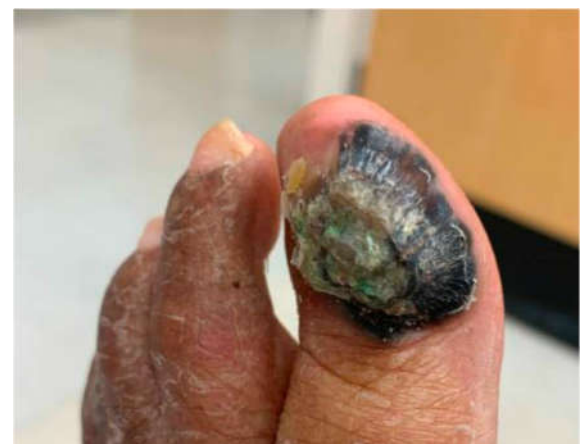**6/2024 MRI LLE WO Contrast:** Left great toe superficial nailbed mass measuring up to 2 cm x 2 cm with likely intraosseous invasion into the distal phalanx.

### Histopathology

**5/2024 Right great toe:** The biopsy demonstrates an infiltrative growth of atypical keratinocyte nests without a granular layer with abundant melanin pigment and small keratocysts with sudden central keratinization lined by atypical keratinocytes.

### Treatment

The patient was referred to orthopedic oncology, who performed partial amputation of the left great toe. Pathology showed complete excision of onycholemmal carcinoma with negative proximal margin.



## **Invasive Pigmented Onycholemmal Carcinoma**

---

Here, we present a case of onycholemmal carcinoma, a rare subtype of squamous cell carcinoma that originates from the nail bed epithelium. Fewer than 20 cases of this entity have been described in the literature. Clinically, these lesions can have a varied clinical presentation, ranging from hyperkeratosis or ulceration of the periungual area to swelling and erythema of the periungual region resembling paronychia to indolent onycholysis, more commonly on the fingernails than toenails. In our case, we describe the first case of pigmented onycholemmal carcinoma in the literature to our knowledge.

Histopathologically, the tumor is characterized by collections of infiltrative nests of atypical keratinocytes and small keratin-filled cysts with atypical squamous epithelium lacking a granular layer. The abrupt keratinization seen in onycholemmal carcinoma is reminiscent of the trichilemmal keratinization seen in proliferating pilar tumors. This shared pattern of keratinization may reflect common cytokeratins expressed in both the nail isthmus and the outer root sheath of the hair follicle.

Onycholemmal carcinomas typically follow an indolent course with cases persisting for years before diagnosis. Bony invasion of the distal phalanx can occur and was suggested by imaging in our case. Regional lymph node metastasis or systemic spread has not been described with this entity. Most cases described in the literature were treated with amputation without evidence of recurrence in follow up. However, given the indolent nature of this tumor, Mohs micrographic surgery and radiation therapy have been used as effective alternatives to amputation, minimizing patient morbidity.

---

### **References**

- Chaser BE, Renszel KM, Crowson AN, et al. Journal of the American Academy of Dermatology. 2013; 68(2): 290-295.  
Telang GH, Jellinek N. Journal of the American Academy of Dermatology. 2004; 56(2): 336-339.

## CASE #6

### Authors

Connie Qiu, M.D., Ph.D.  
Myriam Gonzalez, M.D.  
Johns Hopkins Hospital

### History

A 31-year-old male initially presented to our clinic with new tender growths within a long-standing collection of nodules on the left neck and chest first noted around 5-6 years of age, and previously diagnosed as eccrine spiradenomas 10 years prior with dermatopathologic analysis. Repeat biopsy of new nodules ruled out malignant transformation—a rare complication of long-standing lesions—and the patient was sent to medical genetics for NGS testing.

### Physical Examination

A collection of firm, smooth, blue-hued pink nodules—multiple with overlying telangiectasias—was noted to span the left suprasternal chest, neck, and jawline in a hemicorporal blaschkoid distribution.

### Laboratory Data

#### 11/15/2023 NGS

Mutations in AKT1 resulting in activation of the MTOR/PI3K pathway was seen in multiple biopsy specimens.  
No mutation in the CYLD gene.

### Radiologic Data

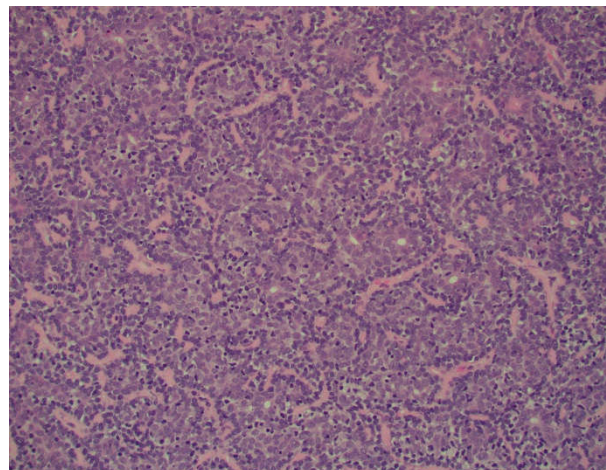
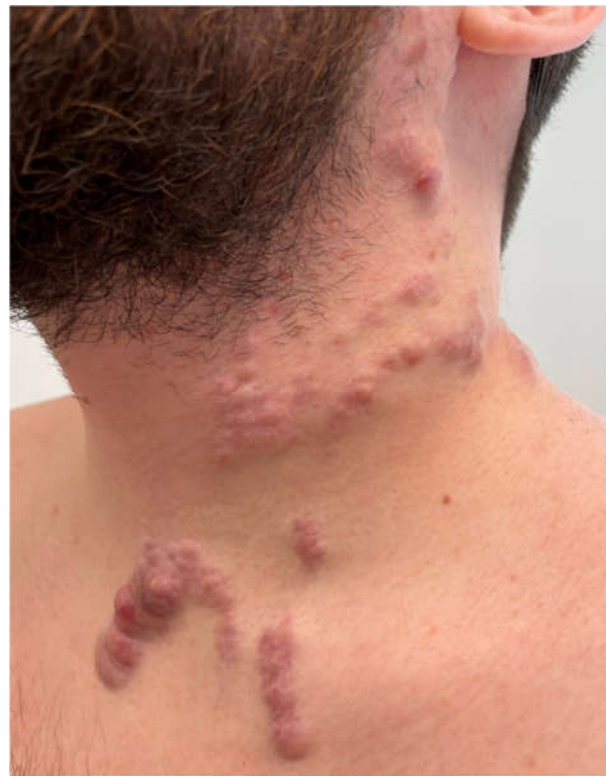**03/15/2024 MRI** Completed for surgical planning. Numerous cutaneous/subcutaneous based clustered lesions extending along the skin surface of the left cheek, postauricular scalp, neck, and anterior chest wall. Most do not extend below the subcutaneous tissue layers, and but a few about the platysma musculature focally without deeper soft tissue extension.

### Histopathology

**11/25/2023, midline and left neck**  
Circumscribed multinodular intradermal basophilic tumor, featuring nests and strands of centrally located pale cells and peripherally located dark basaloid cells outlined by hyaline membrane.

### Treatment

Patient proceeded with elective surgical excision of the most bothersome area, which corresponded to the left anterior neck, despite increased risk of keloid formation along the sternal notch. Excision followed by CO2 ablative laser was performed with plastic surgery in 01/2025.



## Multiple Spiradenomas

---

Spiradenomas are benign entities of adnexal differentiation. They clinically present as subcutaneous papules or nodules which can occur in nearly any location. Clinical appearance of a solitary spiradenoma nodule is not distinctive, and great variance in size and symptoms often necessitates a biopsy for diagnosis. Pathologically, spiradenomas achieve a distinct multinodular pattern with sharply circumscribed basaloid nodules in the dermis, with bland trabecular internal morphology composed of compact basophilic cells.

Most often appearing as a solitary nodule, multiple spiradenomas are rare, and have been reported to reflect linear, zosteriform, nevoid, or blaschkoid distributions. When occurring in multiplicity and/or alongside cylindromas or trichoepitheliomas, the diagnosis of Brooke-Spiegler syndrome or multiple cylindromatosis should be considered, both of which demonstrate autosomal dominant inheritance.

Given our patient's multiple spiradenomas with hemicorporal blaschkoid distribution, we were suspicious for mosaicism, which has been reported in the literature. Additional testing of multiple separate tumor tissues did not identify any change in the *CYLD* gene, making it unlikely that Brooke-Spiegler syndrome is the cause of our patient's multiple spiradenomas. His spiradenomas harbor an *AKT1* mutation, which has been observed in spiradenomas and are thought to contribute to tumor development.

As benign entities with negligible proliferative capacity, treatment is not needed. However, spiradenomas can be tender, and recurrence is uncommon after excision, which our patient chose to undergo for symptomatic and cosmesis preceding his wedding.

---

### References

Rashid M, van der Horst M, Mentzel T, et al. *ALPK1* hotspot mutation as a driver of human spiradenoma and spiradenocarcinoma. *Nat Commun*. 2019 May 17;10(1):2213.

Word A, Sweeney S, Durham K, Hicks L. Somatic mosaicism of eccrine spiradenomas with malignant degeneration and distant metastases. *JAAD* vol 59 issue 5 E257-E258, November 2013

Yui Hirano-Lotman, Yoshihiro Ishida, Hiromi Doi, Seishi Ogawa, Kenji Kabashima, Localized multiple spiradenomas are caused by somatic mosaicism in an *ALPK1* hotspot mutation, *British Journal of Dermatology*, Volume 192, Issue 4, April 2025, Pages 747–749



**CASE #7****Authors**

Eugene N. Brooks, M.D.  
Jeremy Johnson, M.D., Ph.D.  
Meg R. Gerstenblith, M.D.  
The Johns Hopkins Hospital

**History**

Our patient is a 80-year-old Caucasian female with a history of chronic lymphedema of the bilateral lower extremities, bilateral knee replacements, chronic kidney disease (CKD), and bariatric surgery, who presented in early July 2023 with a painful, nodular, ulcerative plaque on the right lower leg. The lesion had been present for 1.5 years despite regular follow-ups at the lymphedema clinic and multiple evaluations by outside vascular surgery and dermatology specialists.

**Physical Examination**

There is a nodular, ulcerative odorous plaque along the right anterior shin wrapping medially to the posterior calf. The background skin is erythematous with prominent indurated edema. Additional violaceous nodules are located proximally to the ulcerative plaque near the right popliteal fossa.

**Laboratory Data** None**Radiologic Data**

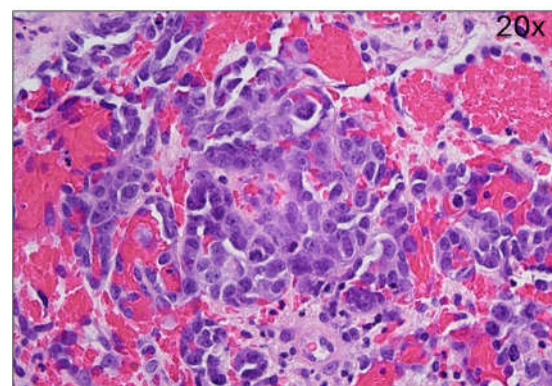
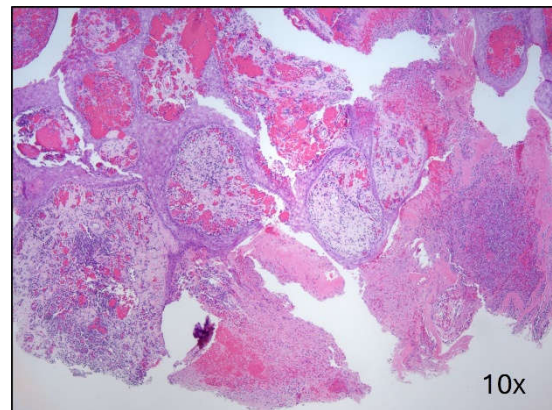
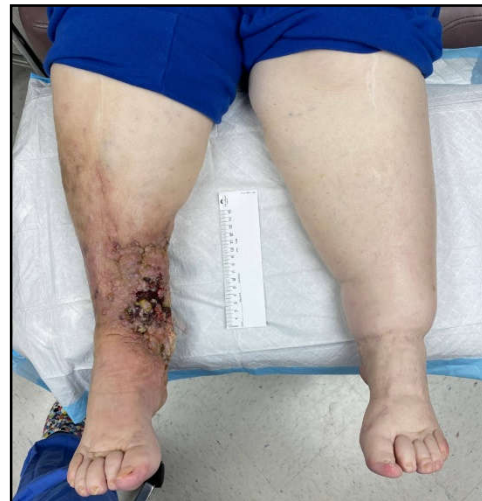(8/30/23, PET/CT whole body). There is right lower extremity soft tissue thickening, ulceration and nodularity with intense FDG uptake. Additional hypermetabolic foci along the posterior right calf, popliteal fossa, right iliac bone, sternum, and multiple ribs are visualized. Bilateral pulmonary nodules are noted as well along with bilateral pleural effusions concerning for metastatic disease.

**Histopathology**

(7/6/23, right posterior calf) Multifocal atypical vascular proliferation with marked nuclear atypia and mitotic activity within a background of dermal edema and overlying epidermal hyperplasia. Immunohistochemistry shows the lesional cells are positive for CD31 and ERG and show diffuse MYC expression. They are negative for HHV8 staining.

**Treatment**

The patient was referred to medical oncology and started on paclitaxel. Unfortunately, she developed neutropenia, delirium and hypotension after one dose of chemotherapy. Decisions were made to transition to hospice care. She passed away 3.5 months after initial presentation to our dermatology clinics.



## Stewart-Treves Syndrome

---

Cutaneous lymphangiosarcoma is a rare complication of chronic lymphedema that carries an overall dismal prognosis. Early detection is crucial for preventing metastatic spread and reducing overall mortality. Stewart-Treves Syndrome (STS) has traditionally been associated with cases of lymphangiosarcoma arising in the setting of postmastectomy lymphedema, first described in a case series published by Dr. Fred W. Stewart and Dr. Norman Treves in 1948. Today, the term has been more broadly applied to lymphangiosarcoma developing in other contexts of chronic lymphedema, including both congenital and acquired etiologies. Notably, 10% of STS cases occur in anatomical locations other than the upper extremities of postmastectomy patients. Fortunately, even among cases associated with radical mastectomy, the incidence remains quite low, estimated at 0.07% to 0.45% of patients who survive at least five years post-mastectomy.

Lymphedema is characterized by tissue swelling caused by the accumulation of lymphatic fluid within interstitial spaces. Primary lymphedema results from developmental abnormalities of the lymphatic system and can be categorized based on the age of onset. Secondary lymphedema is far more common and arises from damage or obstruction of the lymphatic system due to factors like malignant destruction, recurrent infection, filariasis, lymph node dissection, radiation injury, and obesity. The initial presentation of lymphedema typically involves painless, pitting edema of the affected extremity which gradually progresses proximally. Over time, the pitting subsides, and the involved areas become firm, thickened, and leathery in texture. In some severe cases, patients may develop prominent verrucous, cobblestone-like changes of the epidermis, a condition known as elephantiasis nostras verrucosa.

The exact mechanism by which lymphedema induces lymphangiosarcoma remains unknown, though it is postulated that local immunodeficiency associated with chronic lymphatic dysfunction may create an environment conducive to oncogenesis. Clinically, lymphangiosarcoma may present as violaceous macules or patches resembling bruises, or as purple-red nodules that gradually multiply and ulcerate. In advanced stages, necrosis, satellite lesions, and distant subcutaneous nodules may become evident. Histological examination reveals irregular vascular channels dissecting through dermal collagen and subcutaneous tissues. The endothelial cells may appear normal or exhibit pronounced hyperchromatism and pleomorphic atypia. Mitotic figures are often observed. Immunohistochemical studies confirm endothelial origin with lesion cells staining positive for CD31, CD34, and ERG. D2-40, a lymphatic marker for podoplanin, may be variably expressed. High levels of c-MYC gene amplification are frequently observed, similar to those seen in radiation-induced angiosarcomas. Notably, tumor cells are negative for the Kaposi sarcoma biomarker, HHV8. The best chance for long-term survival lies in early amputation or wide local excision with clear margins. In cases where metastatic disease is detected on imaging, surgery may be offered as palliative management. When surgical intervention is not feasible, chemotherapy and radiation therapy can be considered. Some studies suggest that bevacizumab, an anti-angiogenic agent, may help stabilize the tumor and slow disease progression. Despite available treatments, the prognosis remains poor, with reported five-year survival rates ranging from 8.5% to 13.6% and a mean survival of approximately 20 months following tumor onset.

---

### References

Garimella, V., Anand, N., Campbell, E., et al. Lower Extremity Angiosarcoma: A Life-Threatening Complication of Lymphedema. *Advances in Skin & Wound Care*. 2024;37(5):268-270.

Sharma, A., Schwartz RA. Stewart-Treves syndrome: pathogenesis and management. *J Am Acad Dermatol*. 2012;67(6):1342-1348.

## Case #8

### Authors

Ista Egbeto, M.D  
Sima Rozati M.D., Ph.D

### History

Our patient is a 79-year-old woman with a past medical history of Sjogren's syndrome (on hydroxychloroquine) who initially presented with a two-month history of intermittently pruritic subcutaneous nodules on her right arm. Punch biopsies demonstrated a CD30+ lymphoproliferative disorder, initially thought to represent anaplastic large cell lymphoma due to clonal IGH and TCR-G PCR. However, the biopsies further demonstrated positivity for PAX5 and EBV in situ hybridization, consistent with EBV+ diffuse large B-cell lymphoma (DLBCL)

### Physical Examination

There were multiple firm, 1-3cm violaceous nodules on the right arm

### Laboratory Data

10/2024- Plasma EBV viral load was detectable

### Radiologic Data

(10/8/2024, PET/CT)- left axillary lymph node with moderate FDG uptake, new since prior exam.  
(12/20/2024,PET/CT)

There is increasing metabolic activity in bilateral axillary, supraclavicular, and hilar lymph nodes, as well as new low-level radiotracer avid pulmonary nodules

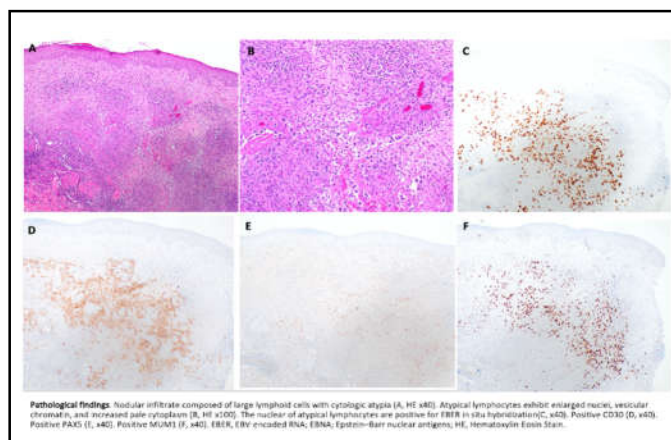
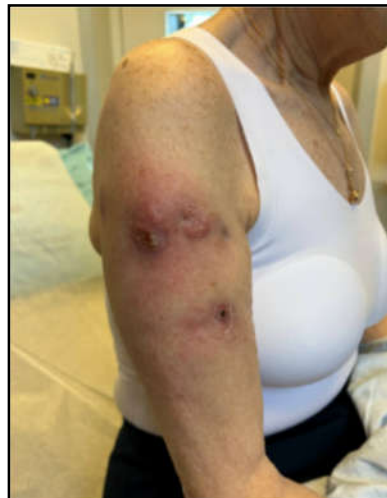### Histopathology

#### (October 17, 2024, Left Arm Punch Biopsy)

The biopsy showed a diffuse infiltrate of large atypical lymphoid cells extending throughout the dermis and subcutis. Immunohistochemical staining reveals positivity for CD20, CD79a, PAX5, MUM1, and BCL-2, with a high Ki-67 proliferation index of 80%. The tumor cells are negative for CD10 and BCL-6. In situ hybridization for Epstein-Barr virus-encoded RNA (EBER) is positive, confirming EBV.

### Treatment

- Initial treatment with rituximab monotherapy (July to November 2024).
- Radiation therapy to bilateral upper extremities (November-December 2024).
- Transitioned to tafasitamab plus lenalidomide in February 2025.



## Primary Cutaneous EBV-positive Diffuse Large B-cell Lymphoma

---

Primary cutaneous Epstein-Barr virus (EBV)-positive diffuse large B-cell lymphoma, not otherwise specified (DLBCL, NOS), is a rare subtype of lymphoma characterized by the presence of EBV-encoded RNA within the tumor cells. This entity is distinct from other EBV-associated lymphomas due to its unique clinical and pathological features.

Clinically, primary cutaneous EBV-positive DLBCL, NOS, often presents with multiple ulcerated and nodular lesions confined to the skin, without systemic involvement. Histologically, the tumor cells exhibit immunoblastic or centroblastic morphology and are typically positive for CD20, PAX-5, MUM1, LMP1, CD30, and EBV-encoded small RNA, but negative for EBNA2.<sup>[1]</sup> The disease can occur in both immunocompromised and immunocompetent individuals, although it is more frequently observed in older adults and in regions with higher EBV prevalence.

The treatment of primary cutaneous EBV-positive DLBCL, NOS, generally involves chemotherapy regimens such as CHOP (cyclophosphamide, doxorubicin, vincristine, and prednisone), often combined with rituximab (R-CHOP).<sup>[1]</sup> The prognosis varies, with some patients achieving complete remission, while others may experience relapse or progression.

Recent genomic studies have identified frequent mutations in genes such as ARID1A, KMT2A/KMT2D, and NOTCH2, as well as structural aberrations like 6q deletions, which distinguish EBV-positive DLBCL from its EBV-negative counterparts.<sup>[2]</sup> These findings suggest potential targets for novel therapeutic approaches, including immunotherapy and targeted therapies.

The World Health Organization (WHO) classification provides a comprehensive overview of the pathological and clinical characteristics of large B-cell lymphomas, including EBV-positive DLBCL, NOS. This classification underscores the importance of accurate diagnosis and tailored treatment strategies for these rare lymphomas.

---

### References

Mo XL, Zhou MY, Ye QR. Primary Cutaneous Epstein-Barr Virus-Positive Diffuse Large B-Cell Lymphoma, Not Otherwise Specified, in a Nonimmunocompromised Young Man: A Case Report. *Journal of Cutaneous Pathology*. 2020;47(4):387-389. doi:10.1111/cup.13602.

Gebauer N, Künstner A, Ketzer J, et al. Genomic Insights Into the Pathogenesis of Epstein-Barr Virus-Associated Diffuse Large B-Cell Lymphoma by Whole-Genome and Targeted Amplicon Sequencing. *Blood Cancer Journal*. 2021;11(5):102. doi:10.1038/s41408-021-00493-5.

Sehn LH, Salles G. Diffuse Large B-Cell Lymphoma. *The New England Journal of Medicine*. 2021;384(9):842-858. doi:10.1056/NEJMra2027612.

**CASE #9****Authors**

Priyanka Kumar, M.D.  
Justin Choi, M.D.  
Myriam Gonzalez, M.D.  
Johns Hopkins University School of  
Medicine

**History**

Our patient is a 42-year-old Caucasian man with a past medical history of hypertension, hyperlipidemia, and solitary kidney cyst who presented to our clinic in the setting of a 20+ year history of numerous asymptomatic white bumps involving the face. Prior management included shave removal (with unknown prior biopsy results), but the areas since recurred.

Family history is notable for multiple family members (including the patient's sister, father, paternal aunt, and paternal grandmother) with similar facial bumps.

**Physical Examination**

There are innumerable, flesh-colored to white, 1-3 mm dome-shaped papules involving the nose and bilateral medial cheeks, and several solitary papules on the lateral cheeks.

**Laboratory Data**

None.

**Histopathology**

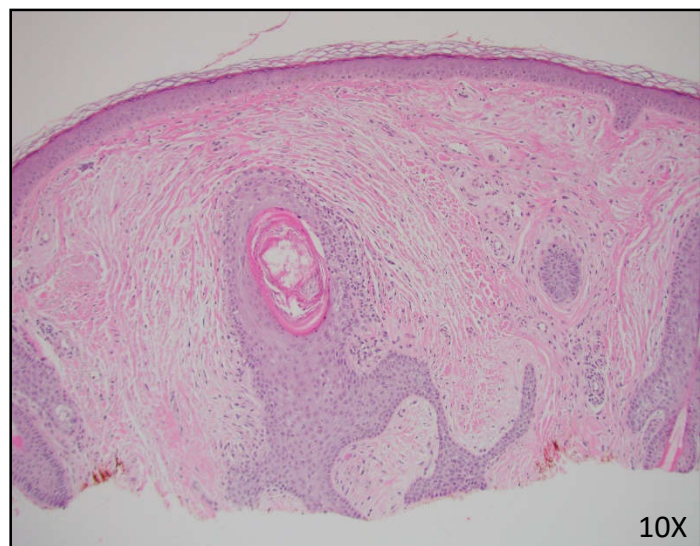
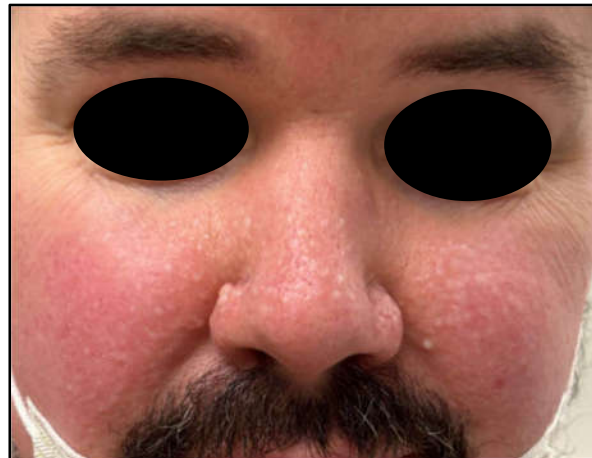**(01/17/2024, Right nasal ala)** The biopsy is consistent with fibrous papules. Note: The lesion appears to represent two fibrous papules, one of which demonstrates prominent myxoid change. Of note, trichodiscomas are known to have angiofibroma-like features.

**(01/17/2024, Right cheek)** The biopsy shows a fibrofolliculoma/trichodiscoma.

**Treatment**

Given the personal and family history of innumerable papules involving the midface and biopsy-confirmed fibrofolliculoma/ trichodiscoma, a presumptive diagnosis was made of Birt-Hogg-Dubé syndrome.

A genetics referral was placed. Genetic testing was notable for the finding of a pathologic variant in FLCN, confirming the diagnosis of Birt-Hogg-Dubé syndrome. The patient was advised to continue routine Dermatology follow-up as well as to complete screening exams for associated conditions (including a baseline CT chest to assess for pulmonary cysts and annual abdominal/pelvic MRI to evaluate for renal tumors).



## Birt-Hogg-Dubé Syndrome

---

First described in 1977, Birt-Hogg-Dubé syndrome (BHDS) is a rare autosomal dominant disease characterized by follicular hamartomas, pulmonary cysts, spontaneous pneumothorax, and renal cell cancer. This condition is caused by germline mutations in the FLCN (folliculin) gene (also referred to as the BHD gene after this disease entity). Mutation analysis among patients with BHDS has found over 50 unique FLCN germline mutations associated with the disease.

BHDS is likely underdiagnosed due to its wide variety of clinical presentation. Some families with the pathogenic gene manifest with evidence of only pulmonary disease (i.e. pulmonary cysts or pneumothorax) whereas other families demonstrate both cutaneous and systemic features. To date, there have been no genotype-phenotype correlations linking specific FLCN mutations to particular clinical manifestations. Among individuals with a FLCN germline mutations, 84% of patients were found to have pulmonary cysts, and 34% of patients were found to have renal tumors.

From a dermatologist's perspective, the clinical manifestations of BHDS involve a spectrum of cutaneous hamartomas (including fibrofolliculomas, angiofibromas, and perifollicular fibromas), trichodiscomas, and acrochordons. Fibrofolliculomas and trichodiscomas are considered a part of a morphological spectrum. Other cutaneous lesions reported with BHDS include malignant melanoma, dermatofibrosarcoma protuberans, and leiomyosarcoma; it is not clear whether these findings are relevant to the BHDS clinical spectrum. Notably, it is estimated that 25% of adults with FLCN germline mutations do not manifest skin lesions.

Genetic testing for FLCN mutation is recommended for patients with suspected BHDS to not only confirm the diagnosis but also to prompt presymptomatic testing (i.e. CT chest to assess for pulmonary cysts, abdominal/pelvic MRI to evaluate for renal tumors) for any at-risk family members. Management of BHDS is driven by the clinical manifestation of disease. For patients with cutaneous disease, various treatment modalities ranging from ablative laser to shave removal to curettage have been tried with mixed response.

---

### References

Birt AR, Hogg GR, Dubé WJ. Hereditary multiple fibrofolliculomas with trichodiscomas and acrochordons. *Archives of dermatology*. 1977;113(12):1674-7.

Menko FH, Van Steensel MA, Giraud S, et al. Birt-Hogg-Dubé syndrome: diagnosis and management. *The Lancet Oncology*. 2009;10(12):1199-206.

Toro JR, Wei MH, Glenn GM, et al. BHD mutations, clinical and molecular genetic investigations of Birt-Hogg-Dubé syndrome: a new series of 50 families and a review of published reports. *Journal of Medical Genetics*. 2008;45(6):321-31.

## CASE #10

### Authors

Andrew R. Tadros, MD, PhD  
Myriam Lucia Vega Gonzalez, MD, MPH  
Johns Hopkins University School of Medicine  
Department of Dermatology

### History

Our patient is a 22-year-old male who presented to our clinic with several painful, progressively enlarging nodules on the left leg over the past 4 months. He denied lesions elsewhere on his body. Of note, he had a history of a painful growth on his left lower leg which was excised and showed a pseudomyogenic hemangioendothelioma (PHE). Due to post-excisional recurrence, osseous spread and evidence of multi-focal pulmonary nodules, he ultimately underwent below knee amputation in December 2023.

### Physical Examination

November 2023 – On the left dorsolateral foot is a ~7-8 cm exophytic and ulcerated vascular plaque with surrounding indurated erythema. Few scattered 0.5 cm violaceous papules on the distal toes.

March-December 2024 – Indurated, violaceous 0.5-0.8 cm smooth, subcutaneous papules on the left leg.

### Laboratory Data

**(12/2024, Next Generation Sequencing)** Mutations predictive of response to treatment with approved or investigational therapies have not been detected.

### Radiologic Data

**(3/2024, PET/CT)** Multiple new pulmonary nodules with minimal FDG uptake highly suspicious for new metastases

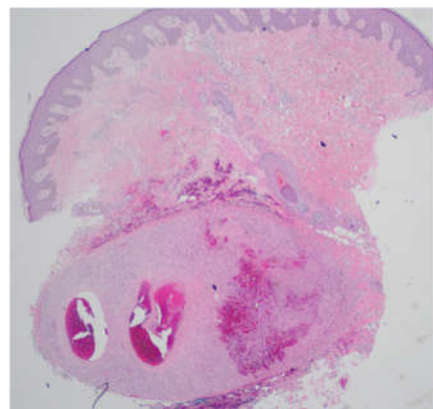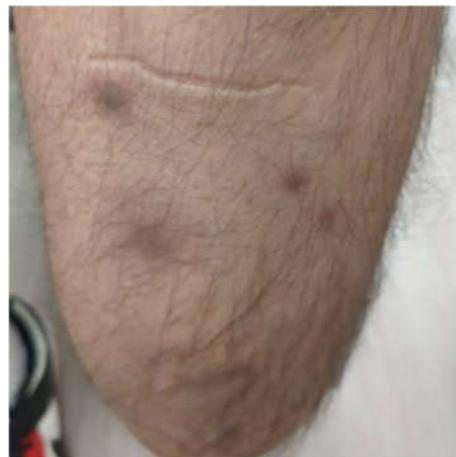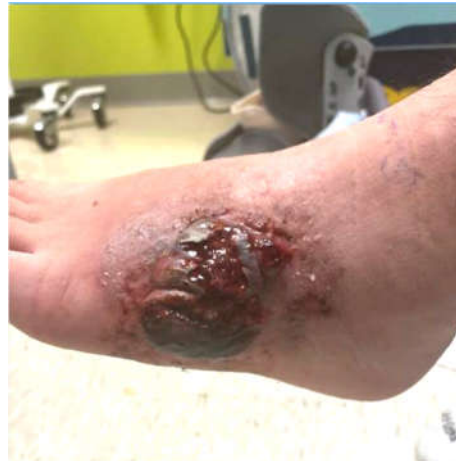**(7/2024, PET/CT)** Overall, stable appearance of multiple bilateral pulmonary nodules

### Histopathology

**(12/2024, left anterior leg)** The biopsy shows a nodular growth with fascicles of plump spindled-epithelioid cells with eosinophilic cytoplasm and variably prominent nucleoli.

### Treatment

Patient underwent below knee amputation in December 2023 given multi-focal disease and osseous spread, and he was also started on everolimus. Given local progression of PHE, oncology ultimately decided to transition from everolimus to pazopanib in January 2025.



## Pseudomyogenic Hemangioendothelioma

---

Pseudomyogenic hemangioendothelioma (PHE) is a rare vascular neoplasm of intermediate malignancy with distinctive pseudomyogenic histological features. Approximately 200 cases have been reported worldwide since it was first classified by the WHO in 2013. PHE primarily affects young to middle-aged adults with a 5:1 male predominance. PHE presents as multiple subcutaneous or intramuscular nodules in the distal extremities. Patients typically present with slowly progressive, painful nodules ranging from millimeters to several centimeters.

PHE likely originates from endothelial cells with aberrant differentiation, resulting in a “pseudomyogenic” phenotype. Histologically, lesions demonstrate epithelioid to spindled cells with abundant eosinophilic cytoplasm arranged in fascicles or nests, interspersed with vascular channels. Immunohistochemical analysis reveals consistent expression of vascular markers (CD31, ERG, AE1/AE3) while lacking true myogenic differentiation markers. The defining molecular hallmark of PHE is the presence of *FOSB* gene rearrangements, most commonly the *SERPINE1-FOSB* fusion, although *ACTB-FOSB* and *WWTR1-FOSB* fusions have also been identified. These genetic alterations result in *FOSB* (detectable by FISH or RT-PCR) overexpression, driving neoplastic proliferation through dysregulation of AP-1 transcription factor activity.

Complete surgical excision with wide margins represents the standard of care, though local recurrence rates of 20-60% have been reported. For unresectable or metastatic disease, treatment options include:

- Radiation therapy as adjuvant treatment or for palliation
- Systemic chemotherapy with mTOR inhibitors (everolimus)
- Emerging therapies directed at tyrosine kinase pathway inhibition (pazopanib)
- Regular imaging/surveillance, especially given the propensity for multifocal disease

Despite a local recurrence rate of approximately 60%, the overall prognosis remains relatively favorable with 5-year survival rates exceeding 90%. Distant metastasis occurs in approximately 5% of cases, primarily to lungs. A multidisciplinary approach involving surgical oncology, dermatology, pathology, and medical oncology is essential for optimal management.

---

### References

Pradhan, D., Schoedel, K., McGough, R. L., et al. (2018). Pseudomyogenic hemangioendothelioma of skin, bone and soft tissue—a clinicopathological, immunohistochemical, and fluorescence in situ hybridization study. *Human Pathology*, 71, 126-134.

Yang, N., Huang, Y., Yang, P., et al. (2023). Clinicopathological study of pseudomyogenic hemangioendothelioma. *Diagnostic Pathology*, 18(1), 25.

Alhanash, A., Aseafan, M., & Atallah, J. (2022). Pazopanib as Treatment Option for Pseudomyogenic Hemangioendothelioma: a Case Report. *Cureus*, 14(5).



## CASE #11

### Authors

Varsha Simha, M.D.  
Leora Aizman, M.D.  
Jihad Alhariri, M.D.  
Johns Hopkins Dept of Dermatology

### History

This is a 77 year old African American female with history of ESRD (hypertensive nephrosclerosis) with living unrelated renal transplant in 2003 presenting with hyperpigmented macules of the bilateral lower extremities. She initially presented in 2017 with eruptive nevi of the hands and feet. One atypical-appearing mole was biopsied on her left lateral foot, showing atypical junctional melanocytic proliferation. At the time, her immunosuppressive medications included prednisone, azathioprine, and tacrolimus. Her 2024 presentation was for full body skin check. At this time, her immunosuppressive medications included tacrolimus 3mg BID, azathioprine 50mg, and prednisone 5mg daily. She was not able to monitor the lesions on the feet due to poor mobility. These macules were otherwise asymptomatic. Three punch biopsies were performed. The right lateral plantar foot showed atypical intra-epidermal melanocytic proliferation. The left distal plantar foot (larger lesion) showed atypical compound acral nevus. The left distal plantar foot (smaller lesion) showed junctional acral nevus.

### Physical Examination

Physical exam showed three dark brown macules on the left foot (two distal, one central) and two dark brown macules on the right foot (one lateral and one central) with parallel ridging on dermoscopy. Compared to images taken in 2017 at the time of her first AIMP, all left foot lesions were present but much smaller and darker. The central right foot lesion was present and similar to prior, while the anterolateral macule was new.

### Histopathology

**(05/23/2017, left lateral foot):** Atypical junctional lentiginous melanocytic proliferation, present at lateral margins.

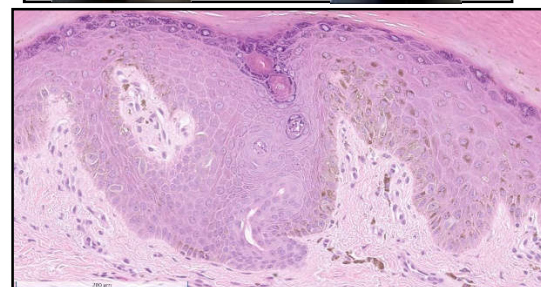
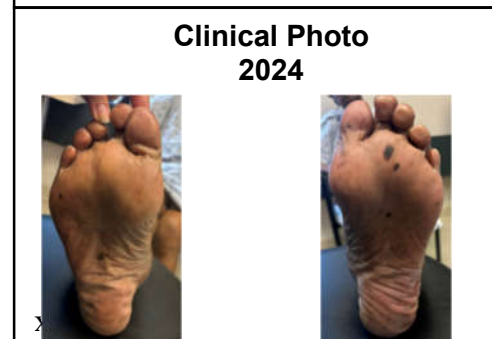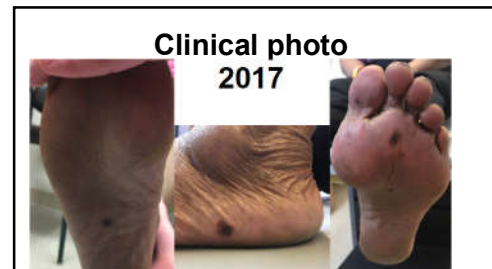**(10/22/2024, right lateral plantar foot):** Atypical intradermal melanocytic proliferation, narrowly excised on planes of section examined.

**(10/22/2024, left distal plantar foot A):** Consistent with atypical compound acral nevus, present at lateral margins.

**(10/22/2024, left distal plantar foot B):** Consistent with junctional acral nevus, present at the lateral margins.

### Treatment

For the lesion in 2017, she underwent wide local excision with complete resection of the lesion. She is pending the same treatment for the atypical lesion on the right foot with continued monitoring for lesions on the left foot.



## Eruptive Atypical Melanocytic Proliferations in a Renal Transplant Patient

---

There are limited data regarding eruptive nevi, including atypical or malignant nevi, of acral sites in the setting of transplant or immunosuppression.

A 1988 paper detailed eruptive non-acral dysplastic nevi in a patient after renal transplantation, who was on azathioprine and prednisolone daily. Biopsies of multiple new nevi showed melanocyte atypia and enlargement and bridging of rete. There are case reports of eruptive melanocytic proliferations on the hands and feet in the setting of immunosuppressive therapy, such as an 18 year old on mercaptopurine for two years for Crohn's disease. Similarly, a 25 year old patient on prednisone and azathioprine for several months in the setting of Crohn's disease developed pigmented macules on her palms and soles.

There are limited studies or case reports examining risk of malignant transformation of acral nevi in the setting of immunosuppression. Of course, there is a known relationship between immunosuppression and skin cancer. While the exact incidence of de novo melanoma in patients with solid organ transplants, there are studies suggesting 2.1 to 8-fold risk of melanoma in this patient population compared to the general population.

The mechanism of development of these melanocytic proliferations has been proposed to be due to altered immune surveillance and certain anatomic factors in acral sites. These anatomic factors include increased density of eccrine sweat glands and absence of apocrine and pilosebaceous units. Notably, eccrine glands express MC5R receptors, which bind melanocyte stimulating hormone (MSH), while the agouti signaling protein produced by hair follicles acts as an antagonist to MSH. Therefore, palmoplantar skin lacking the latter protein may not have the mechanism to oppose the function of MSH. While azathioprine is thought to contribute to melanocyte growth and proliferation due to immunosuppression, tacrolimus may exert both immunosuppressive and more direct effects on melanocytes. Studies investigating the direct effect of tacrolimus on cultured human melanocytes showed promotion of cell migration and tyrosinase activation. Additionally, this medication may act on keratinocytes to create a favorable condition for melanocyte growth, including stem cell factors.

A Delphi consensus guiding screening after solid organ transplant suggests that high risk Caucasian patients should be screened within 2 years after transplant. Additionally, all Caucasian, Asian, Hispanic, and high-risk African American patients should be screened within 5 years after transplant. Although treatment for atypical melanocytic proliferations not reaching the diagnosis of melanoma-in-situ is unclear, many dermatologists may opt for full excision or frequent monitoring.

---

### References

- Barker JN, Macdonald DM. Eruptive dysplastic naevi following renal transplantation. *Clinical and Experimental Dermatology*. 1988;13(2):123-125.
- Kubica AW, Brewer JD. Melanoma in Immunosuppressed Patients. *Mayo Clin Proc*. 2012;87(10):991-1003.
- Prabhu AV, Bibee K, English JC. Eruptive Melanocytic Acral Nevi in the Setting of 6-mercaptopurine Therapy. *Journal of Drugs in Dermatology*. 2017;16(5):516.
- Woodhouse J, Maytin EV. Eruptive nevi of the palms and soles. *Journal of the American Academy of Dermatology*. 2005;52(5):S96-S100.
- Zattra E, Fortina AB, Bordignon M, et al. Immunosuppression and melanocyte proliferation. *Melanoma Research*. 2009;19(2):63-68.

**Case #12****Authors**

Michelle A. Robinson M.D.  
Connie Cai, B.A.  
Robert Smith, M.D.  
Department of Dermatology  
Johns Hopkins School of Medicine

**History**

A 15-year-old immunocompetent male with a history of atopic dermatitis and dyshidrotic eczema managed with topical corticosteroids presented to the pediatric dermatology clinic with a 6–7 month history of worsening, mildly pruritic papular lesions on the dorsal hands. Due to persistent, refractory eczema, he had been applying mid-to-high potency topical corticosteroids to the affected areas. He additionally frequently washed dishes while wearing gloves that were later found to be contaminated with black mold.

**Physical Examination**

On exam, there were diffuse monomorphic pink-to-violaceous dome-shaped, flat-topped, umbilicated papules of the dorsal fingers, hands, and wrists, with notable sparing of the palms.

**Histopathology**

**(Punch biopsy 9/27/24, Right dorsal hand,**  
The biopsy showed granulomatous dermatitis concerning for infection.

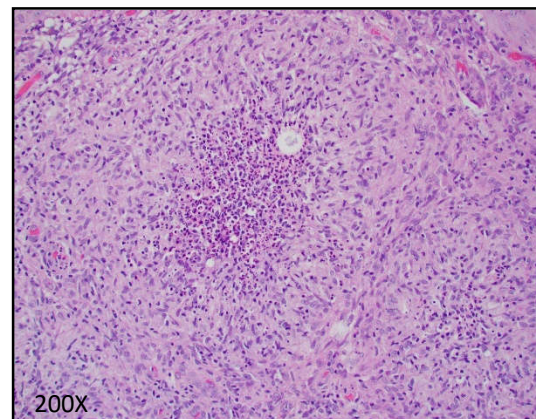
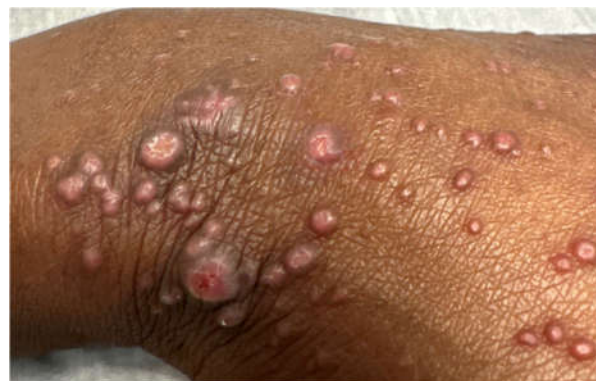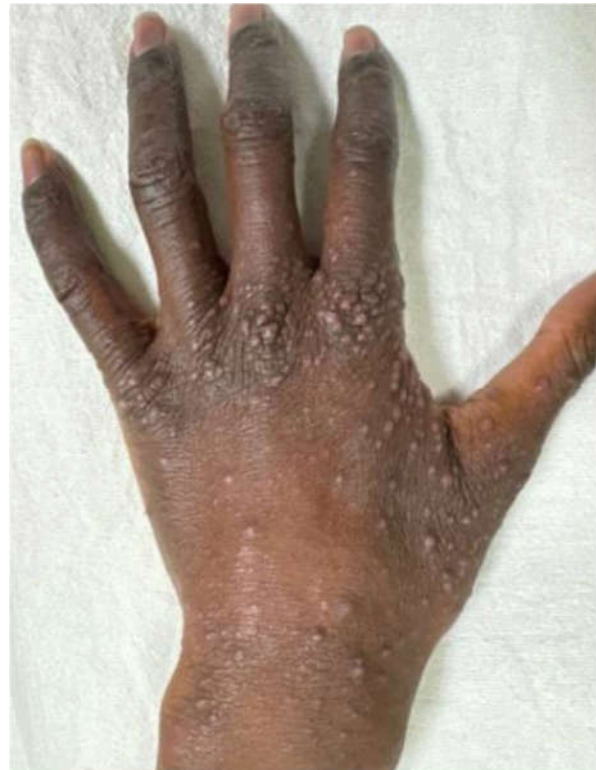**Laboratory Data**

**Abnormal: 10/20/24**

Tissue culture was positive for *Mycobacteria chelonae* & *Mycobacterium septicum*.

**Treatment**

He was empirically treated with doxycycline and azithromycin and then transitioned to trimethoprim/sulfamethoxazole and continued azithromycin after susceptibilities resulted. He was referred for immunologic workup which was unremarkable. His lesions are improving; infectious disease recommends continuing the antibiotic treatment for at least 4-8 more weeks pending complete resolution of symptoms.



## Cutaneous Nontuberculous Mycobacterial Infection

---

*M. chelonae* is one of the three most common nontuberculous mycobacterial (NTM) infections and is well-documented in both immunocompromised and immunocompetent individuals. It primarily manifests as skin and soft tissue infections, often following trauma or surgical procedures, with a predilection for extremities due to its optimal growth at 30–32°C. In contrast, *M. septicum* is a rarely identified pathogen, first reported in a pediatric central line infection and primarily associated with catheter-related infection. Only a few cases of *M. septicum* skin and soft tissue infections have been documented.

Clinically, *M. chelonae* infections present as erythematous papules, nodules, or pustules that may ulcerate or form abscesses. Lesions often persist despite standard antibiotics, prompting further microbiologic evaluation. *M. septicum* has been isolated from clinical specimens in several cases, though its clinical significance is uncertain and it is often not considered a true pathogen. Its role in this patient remains uncertain, but co-isolation with *M. chelonae* suggests it may have contributed to the clinical presentation.

Treatment of *M. chelonae* typically involves dual therapy with a macrolide (e.g., clarithromycin or azithromycin) and amikacin for invasive or refractory cases, while localized infections may respond to clarithromycin monotherapy. However, empiric monotherapy for atypical mycobacteria is generally contraindicated due to the risk of resistance. *M. chelonae* is resistant to cefoxitin, whereas *M. septicum*, in contrast, is resistant to clarithromycin and doxycycline but remains susceptible to amikacin, ciprofloxacin, imipenem, linezolid, moxifloxacin, and trimethoprim-sulfamethoxazole. Due to its rarity, there are no established treatment guidelines for *M. septicum*. A dual infection with *M. chelonae* and *M. septicum* has not been previously reported in the literature. The rarity of *M. septicum* infections likely explains this absence. Given that most *M. septicum* isolates have been incidental, its presence here may represent an environmental contamination or an underrecognized pathogenic potential. In contrast, *M. chelonae* is a well-established cause of cutaneous infections, making it the more likely driver of this patient's disease presentation.

---

### References

Akram SM, Rathish B, Saleh D. c. In: *StatPearls*. Treasure Island (FL): StatPearls Publishing; August 8, 2023.

Go JR, Wengenack NL, Abu Saleh OM, Corsini Campioli C, Deml SM, Wilson JW. Mycobacterium septicum: a 6-Year Clinical Experience from a Tertiary Hospital and Reference Laboratory. *J Clin Microbiol*. 2020;58(12):e02091-20. Published 2020 Nov 18. doi:10.1128/JCM.02091-20

Hogg GG, Schinsky MF, McNeil MM, Lasker BA, Silcox VA, Brown JM. Central line sepsis in a child due to a previously unidentified mycobacterium. *J Clin Microbiol*. 1999;37(4):1193-1196. doi:10.1128/JCM.37.4.1193-1196.1999

Brown-Elliott BA, Philley JV. 2017. Rapidly Growing Mycobacteria. *Microbiol Spectr* 5:10.1128/microbiolspec.tnmi7-0027-2016. <https://doi.org/10.1128/microbiolspec.tnmi7-0027-2016>

**CASE #13****Authors**

Breanna Nguyen, M.D.  
Jihad Alhariri, M.D.

**History**

Our patient is a 63 year old female with history of systemic sclerosis on Myfortic who initially presented with herpes zoster involving the left face, left chest, and left upper back. Due to concern for disseminated zoster, she stopped Myfortic at onset. She initially received IV acyclovir for 3 days and was transitioned to PO valacyclovir for 11 days after papules stopped progressing and began to heal. She re-presented to our clinic on 2 weeks later due to the appearance of new papules on the face and shoulders, despite completing valacyclovir. Lesions were swabbed for viral PCR at this time. Her anti-viral course was extended for another 2 weeks and was instructed to follow up again after completing the medication. At next follow up, the papules on the chest and face had significantly improved but she had a persistently tender dermatomal cluster of papules on the left lateral back.

**Physical Examination**

At the left lateral back, there is a dermatomal cluster of erythematous pink smooth papules. At the left chest, there are flat and scaling erythematous light pink macules that appear faded from prior exam.

**Laboratory Data**

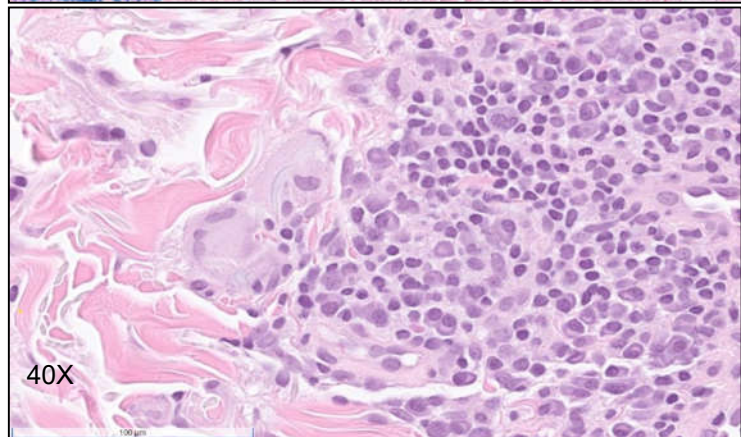
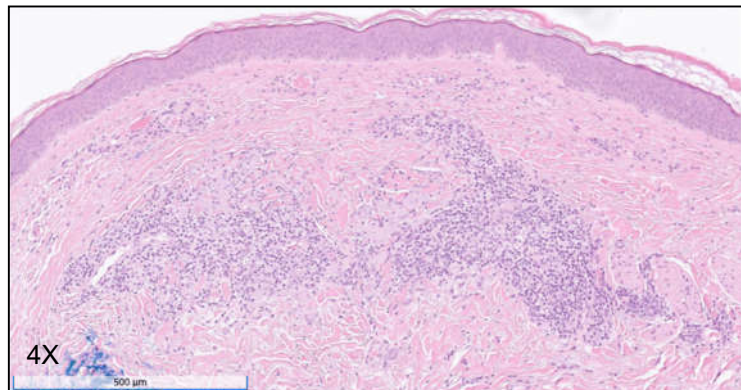
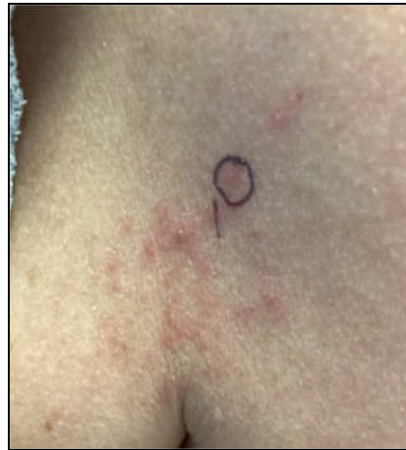1/3/24: VZV PCR positive

**Histopathology**

(1/17/2024, left lateral back) The biopsy shows granulomatous dermatitis.

**Treatment**

Given no evidence of active viral changes on pathology, we restarted her Myfortic and treated with topical betamethasone 0.05% cream. The patient informed us that the rash and tenderness completely resolved with topicals over the next 3-4 weeks.



---

## VZV Granulomatous Dermatitis

---

VZV associated granulomatous dermatitis is a delayed inflammatory reaction that develops at sites of previous zoster infection, representing an isotopic response. This condition manifests as erythematous to violaceous papules or plaques in a distribution of prior VZV infection. It can be associated with post-herpetic neuralgia. It typically appears weeks to months after the acute infection resolves, with a case series and retrospective review finding an average onset of 4.2 months after the initial infection (range, 0.1 – 36 months) (McCoy et al., 2018). In a case series reviewing 26 biopsy specimens taken from patients who presented with new cutaneous lesions in areas of previous zoster infection, VZV associated granulomatous dermatitis histologically showed an interstitial granulomatous dermatitis with lymphocytes, histiocytes, and multinucleated giant cells displaying elastophagocytosis in addition to a perineural, perivascular, and periadnexal mononuclear inflammatory infiltrate rich in lymphocytes and plasma cell rich (Ferenczi et al., 2015). Of note, the finding of a lymphocyte and plasma cell rich perineural infiltrate was a prominent and distinct finding in 23/25 cases where nerves were identified on histology (Ferenczi et al., 2015).

While VZV associated granulomatous dermatitis can affect both immunocompetent and immunocompromised individuals, McCoy et al. found that approximately 43% of cases occur in immunocompromised patients, with chronic lymphocytic leukemia (CLL) being the most common association. Significant postherpetic neuralgia often accompanies this condition, particularly in immunocompromised patients (Wright et al., 2014).

This is primarily a clinical diagnosis, however obtaining a biopsy can be helpful to show characteristic granulomatous inflammation and rule out active viral cytopathic change. PCR testing for VZV DNA provides inconsistent results and may still be positive in early granulomatous lesions (within 4-5 weeks) but typically negative in later lesions (Wright et al., 2014). Treatment focuses on managing both cutaneous manifestations and associated neuralgia. Topical or intralesional corticosteroids and calcineurin inhibitors are used for skin lesions, while postherpetic neuralgia requires multimodal approaches (Wright et al., 2014). Importantly, antiviral medications are ineffective for established VZV associated granulomatous dermatitis as it represents an immune-mediated reaction rather than active viral infection (Wright et al., 2014; Ferenczi et al., 2015).

The overall prognosis is good with most cases resolving over weeks to months with topical therapies. However, immunocompromised patients may experience more prolonged disease, and postherpetic neuralgia may persist despite resolution of cutaneous findings (McCoy et al., 2018),

---

### References

McCoy, Otchere, Musiek, and Anadkat et al. Granulomatous dermatitis as a postherpetic isotopic response in immunocompromised patients: A report of 5 cases. *JAAD Case Reports*. 2018;4:752-60.

Ferenczi, Rosenberg, McCalmont, et al. Herpes zoster granulomatous dermatitis: histopathologic findings in a case series. *J Cutan Pathol* 2015;42:739-745

Wright, Torres-Cabala, Curry, et al. Post-Varicella Zoster Virus Granulomatous Dermatitis. A report of 2 cases. *Cutis* 2014;93:50-54.

## CASE #14

### Authors

Breanna Nguyen, MD  
Leora Aizman, MD  
Jihad Alhariri, MD

### History

Our patient is a 37 year old female with history of hypertension, iron deficiency anemia, and atopic dermatitis in childhood, who presents with a 6 month history of asymptomatic brown papules on the upper back. She was in her normal state of health and denied prior infection, trauma, or contacts at the affected site. Her tattoo was completed 15 years prior. No personal or family history of sarcoidosis or other autoimmune diseases. She tried treating with hydrocortisone 1% cream and incidentally noticed that the papules became flatter after finishing a short burst of prednisone (20mg x 3d) for an irritant dermatitis on the legs.

### Physical Examination

At the upper back, there is a cluster of shiny brown papules.

### Laboratory Data

5/2023

Negative fungal, mycobacterial, and bacterial tissue cultures.

7/2023

Normal: WBC, CMP

**Abnormal:** Hgb 10.2 (12-15); Plt 468 (150-350)

### Radiologic Data

5/2023, CXR: There are small bilateral calcified hilar and mediastinal lymph nodes, which may be sequela of prior granulomatous disease. No bulky hilar lymphadenopathy.

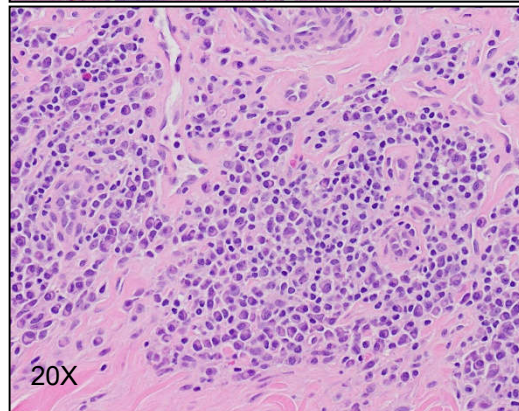
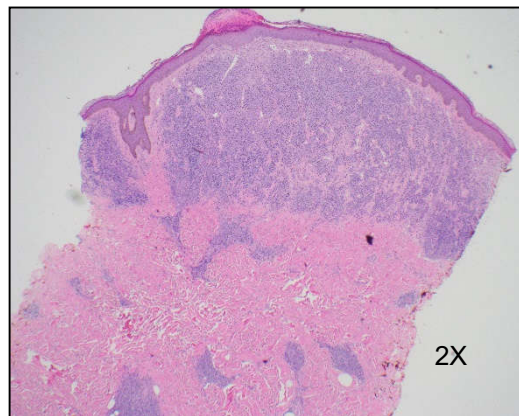
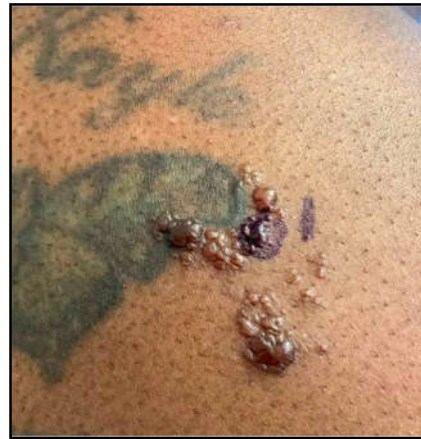
### Histopathology

5/16/23, upper back: The biopsy shows granulomatous dermatitis. No polarizable material identified.

5/31/23, upper back: The biopsy shows dermal lymphoplasmacytic infiltrate, favored reactive. The plasma cell component showed good kappa and lambda expression without light chain restriction.

### Treatment

Our patient deferred initiating topical treatment and completing workup for other systemic diseases, since the papules were asymptomatic and she was otherwise feeling well. We recommended obtaining CT chest, TB, Lyme Ab, T. pallidum Ab, VZV IgM, Serum immunoglobulins, IFE, K/L free LC, C3/C4, serum ACE.



## Lymphoplasmacytic Plaque

---

Lymphoplasmacytic plaque is a recently described and uncommon cutaneous eruption that clinically manifests as red to brown grouped or linear papules and plaques. It frequently involves the lower legs, is typically asymptomatic, and can persist for years. While initially described as a pretibial condition in Caucasian children, recent case series by Mitteldorf et al. provides evidence of occurrence in non-Caucasian adults and in non-tibial locations, including upper extremities, trunk, and digits. In this case series which included 16 cases, the largest cohort reported in the literature to date, lymphoplasmacytic plaques showed a female predominance (7:1) and affected patients with a mean age of 19.6 years (range, 2-66 years) with 4/16 cases being adults. Of note, previous case reports were primarily pediatric cases spanning 2 – 17 years (Porto et al. 2016, 2013). The presentation of our patient is another example showing that lymphoplasmacytic plaque is not solely a pediatric entity, can be seen in skin of color, and can affect areas of the body other than the lower extremity.

On pathology, lymphoplasmacytic plaques show a dense mixed infiltrate of lymphocytes and plasma cells with or without epithelioid granulomas and giant cells. On histopathologic review, the inflammatory infiltrates were lichenoid, deep nodular and interstitial, or a combination of both (Mitteldorf et al. 2015). Granulomas and giant cells were identified in 30% of those cases. Other common findings on histology included acanthosis, parakeratosis, and histiocytes surrounding collagen bundles termed “histiocytic pseudorosettes.”

Given the presence of plasma cells and granulomas, the differential diagnosis should remain broad and aim to exclude underlying systemic diseases. Due to presence of plasma cells, the differential should include lymphoproliferative diseases and cutaneous plasmacytosis. Immunohistochemistry can confirm polyclonality of plasma cells, helping differentiate this entity from lymphoproliferative disorders. Presence of granulomas should prompt investigation to rule out infection (Lyme, T. pallidum, mycobacterial infection, leishmaniasis), foreign body reaction, or sarcoidosis.

Treatment options primarily include topical or intralesional corticosteroids with mixed efficacy in the literature. In a case report by Porto et al. (2016), intralesional triamcinolone (3mg/mL) was able to cause flattening of the plaque more effectively than topical triamcinolone. However, in the Mitteldorf et al. case series, topical and intralesional steroids caused partial improvement in 3 patients and no improvement in 2 patients. Other treatment modalities reported in the literature include surgical excision which did result in complete remission and PDL to address erythema (Mitteldorf et al. 2015, Porto et al. 2013).

---

### References

Mitteldorf, Palmedo, Kutzner, et al. Diagnostic approach in lymphoplasmacytic plaque. *J EADV* 2015; 29, 2206-2215.

Porto, Powers, Patel, et al. Lymphoplasmacytic Plaque in Children: A demonstrative case of an emerging clinicopathologic entity. *Pediatric Dermatology* 2016;33 (6): 349-350

Porto, Sutton, Wilson, et al. Lymphoplasmacytic plaque in children: a report of two new cases with a review of the literature. *J Cutan Pathol* 2013;40: 50-55



## CASE #15

### Authors

Raghav Tripathi, M.D., M.P.H.  
Anna Chien, M.D.  
Johns Hopkins Hospital, Baltimore, MD,  
USA

### History

Our patient is a 72 year old woman with past medical history of colorectal cancer, hepatitis C, and hepatocellular carcinoma (HCC; resected 11/2021). She was treated with gemcitabine/cisplatin and durvalumab from 9/2023-10/2023, and then atezolizumab and bevacizumab from 10/2023 to present. On 3/28/24 (after restarting Cycle 8 Dose 1 on 3/8/24), she was admitted to the hospital for a severe, painful groin rash involving the anal and vulvar area, leading to inability to walk.

### Physical Examination

Involving the gluteal cleft, perianal skin, and vulva are well-defined white, wrinkled, shiny, cigarette-paper-like plaques with thin erosions and ulcerations.

### Laboratory Data

None

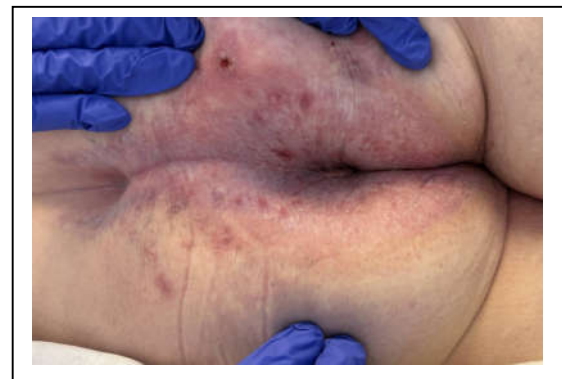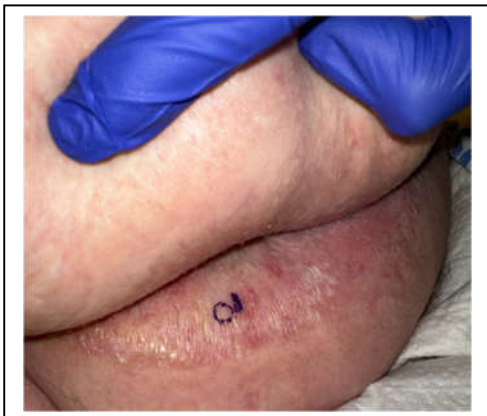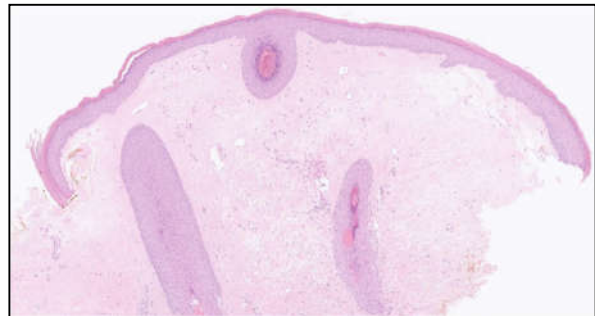
### Histopathology

#### 3/29/24; Right Buttock

The biopsy revealed sparse inflammation, hyperkeratosis, atrophy of the epidermis with loss of rete ridges and plugging of follicular infundibulae, vacuolar degeneration of the basal layer, and broad condensation of dermal collagen. Taken together, these findings are consistent with lichen sclerosis.

### Treatment

Our patient was initially managed with clobetasol ointment, which led to mild symptomatic improvement. She then underwent a prednisone taper due to severe burning and pruritus, which led to resolution of symptoms, but recurrence upon discontinuation. She had significant improvement on methotrexate (15 mg weekly), but this was discontinued due to nausea and fatigue. Given the importance of ongoing HCC treatment, she was restarted on atezolizumab/bevacizumab while undergoing treatment for ICI-induced LS. She started acitretin 10 mg daily and hydroxychloroquine 200 mg daily, which led to complete resolution of her symptoms and erosions after three months. However, she recently had symptomatic recurrence, and will be increasing her acitretin dose to 25 mg daily. She is continuing clobetasol ointment twice daily for flares, and three times weekly for maintenance therapy when not flaring.



## PD-L1 Inhibitor-Induced Erosive Lichen Sclerosus

---

Lichen sclerosus (LS) is a chronic, often debilitating condition marked by pruritus and pain, which most often affects the anogenital area in women. Histologically, LS is characterized by inflammation, epithelial atrophy, and characteristic broad condensation of dermal collagen. The etiology of LS is thought to be multifactorial, though it has been associated with several autoimmune diseases (including vitiligo and alopecia areata). Additionally, autoantibodies against extracellular matrix protein 1 (ECM1) have been reported in LS (Oyama et. al. 2003). Here, we present a unique case of erosive LS induced by immune checkpoint inhibition (ICI) with atezolizumab.

Immune checkpoint inhibitors have been associated with a wide range of cutaneous side effects, most commonly lichenoid, morbilliform, and eczematous dermatoses. ICI-induced LS is extraordinarily rare; when compiling the published literature (PubMed, Google Scholar, FDA Adverse Events Reporting System, Cochrane, etc.), 21 cases of ICI-induced LS have previously been reported (Truong et. al. 2022). The highest risk of incidence is reported in patients on nivolumab and pembrolizumab, and there were no prior reports of atezolizumab-induced LS. Over 90% of patients had excellent response to topical steroids, and almost all patients experienced complete remission once their immunotherapy regimen was complete (Shin et. al. 2023). In a case series of 11 patients with ICI-induced LS, the median age was 64 years (patients tended to be younger than traditional LS), and the median time to onset of symptoms was four months (ranging from three weeks after starting to two months after treatment discontinuation). Most other cutaneous adverse effects from ICI manifest within 3-9 weeks of initiation; in our patient and other reported cases, ICI-induced LS occurs comparatively later in the course of immunotherapy (Alharbi et. al. 2022). Of note, LS can be asymptomatic; it is unclear if ICI leads to true new-onset LS or exacerbation of existing dormant LS.

Continued surveillance of patients with LS is important, due to increased risk of squamous cell carcinoma and vulvar intraepithelial neoplasia. There is no standardized treatment regimen for patients with LS who continue to have active disease despite use of topical steroids, though previously reported options include acitretin, phototherapy, topical calcineurin inhibitors, methotrexate, mycophenolate mofetil, and fractional CO2 laser. This case highlights a potential management approach for a rare case of PD-L1 inhibitor-induced erosive LS.

---

### References

Alharbi A, Khojran A, Noor A et. al. Risk of Lichen Sclerosus and Lichen Planus in Patients Receiving Immune Checkpoint Inhibitors. *Int J Environ Res Public Health*. 2022 Dec 29;20(1):580. doi: 10.3390/ijerph20010580. PMID: 36612904; PMCID: PMC9819784.

Oyama N, Chan I, Neill SM et. al. Autoantibodies to extracellular matrix protein 1 in lichen sclerosus. *Lancet*. 2003 Jul 12;362(9378):118-23. doi: 10.1016/S0140-6736(03)13863-9. PMID: 12867112.

Shin L, Smith J, Shiu J et. al. Association of lichen sclerosus and morphea with immune checkpoint therapy: a systematic review. *Int J Womens Dermatol*. 2023 Jan 19;9(1):e070. doi: 10.1097/JW9.000000000000070. PMID: 36700160; PMCID: PMC9851696.

Truong K, Jones-Caballero M, Chou S et. al. Lichen sclerosus and immune checkpoint inhibitors: A case and review of the literature. *Australas J Dermatol*. 2023 Feb;64(1):158-161. doi: 10.1111/ajd.13941. Epub 2022 Oct 31. PMID: 36310527.

**CASE #16****Authors**

Jerry Tsai, M.D., M.P.H.,  
Jun K. Kang, M.D.  
Johns Hopkins University School of Medicine

**History**

17-year-old Caucasian F who presented with pruritic rash on the left chest, upper arm, and hand for around 1.5 years, persistent despite treatment with topical steroids and topical tacrolimus. She had no fevers, fatigue, weight loss, headache, alopecia, ocular or sinus symptoms, oral lesions, chest pain, shortness of breath, palpitations, abdominal symptoms, diarrhea, bloody stool, joint swelling or stiffness, or Raynaud's phenomenon. There is family history of psoriasis in father, lupus in paternal grandmother, and undifferentiated connective tissue disease in older sister.

**Physical Examination**

Well-defined erythematous, slightly purple plaques on the left chest, left upper arm, and left dorsal hand, in a Blaschkoid distribution.

**Laboratory Data**

(12/2022)

**Normal:** C3, C4, IgG, IgM, ANA, APS panel, dsDNA, SS-B, RNP, Ro52, Ro60, Scl70, Smith, TTG IgA, Jo-1, Ku, EJ, Mi-2, OJ, PL-12, SRP, U1RNP, U2RNP

**Abnormal:** IgA, 315 mg/dL (65-270 mg/dL)

(4/2023)

**Normal:** ANA, APS panel, dsDNA, SS-B, SS-A, RNP, Smith

(12/2023)

**Normal:** C3, C4, ANA, Jo-1, Ku, MDA-5, EJ, Mi-2, MJ OJ, PL-12, SRP, PM-Scl, Ro60, U1RNP, U2RNP

**Abnormal:** P155/140 Ab, positive

(7/2024)

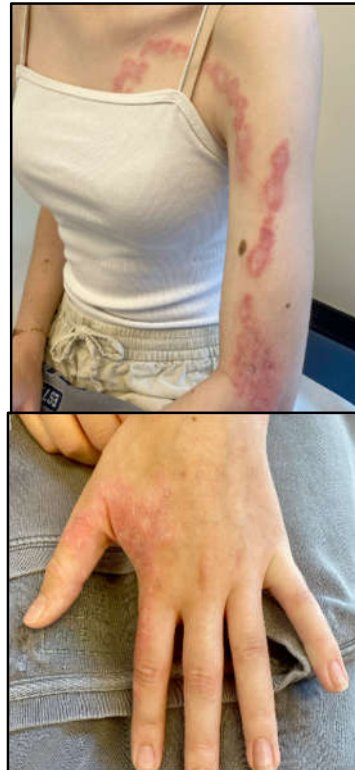**Normal:** C3, C4, dsDNA

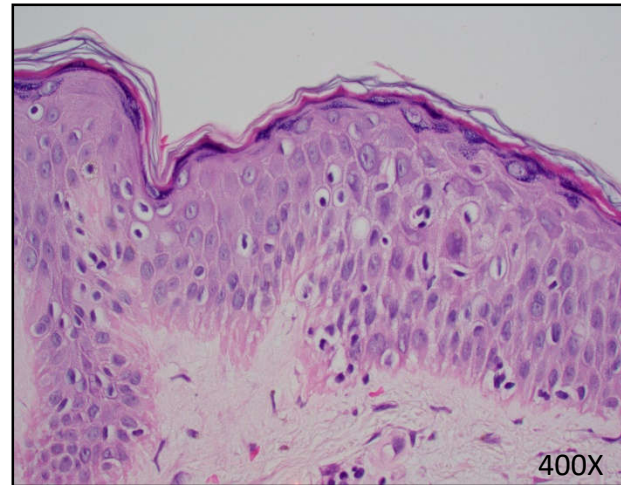
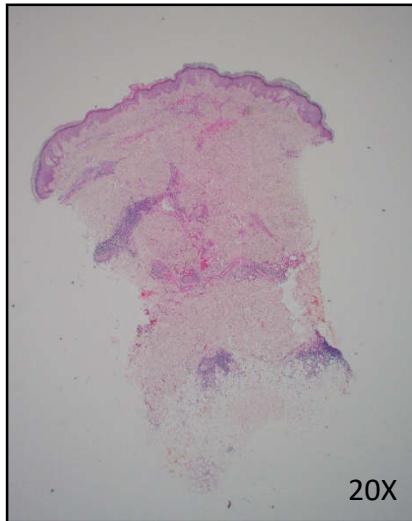
**Histopathology**

**(9/26/23, left lateral arm)** The biopsy showed superficial and deep perivascular dermatitis with focal interface dermatitis, which could be seen in partially treated chronic cutaneous lupus or lichen striatus. Direct immunofluorescence was negative

**Treatment**

The patient was initially treated with topical clobetasol 0.05% cream and topical tacrolimus 0.1% ointment. Due to persistence of skin lesions, she was started on oral hydroxychloroquine 200 mg daily, increased to current dose of 200 mg alternating with 400 mg daily. She has also been on oral methotrexate, initially 10 mg weekly and now at 20 mg weekly. Most recently, she was additionally started on quinacrine. The patient previously had improvement with an oral prednisone taper and no response to tofacitinib 2% cream and intramuscular triamcinolone.





## Linear Cutaneous Lupus Erythematosus

---

Linear cutaneous lupus erythematosus presenting along the lines of Blaschko is a rare presentation of cutaneous lupus. Its pathogenesis is thought to involve mosaic abnormal skin cells with genetic or epigenetic abnormalities along the lines of Blaschko. A systematic review of linear cutaneous lupus erythematosus in 2016 identified 93 cases in the literature across 17 countries. There was no predilection by sex, and nearly half of the cases occurred in individuals under the age of 18. Lesions were most frequently seen on the head, followed by the upper limbs, trunk, neck, and lower limb. Pathologic features of skin lesions varied across patients and encompassed various subtypes of cutaneous lupus, most commonly discoid lupus erythematosus, followed by lupus erythematosus panniculitis, tumid lupus erythematosus, subacute cutaneous lupus erythematosus, and bullous lupus erythematosus. There was positive ANA in 28% of cases and anti-SSA/Ro antibodies in 7.5% of cases. Otherwise, immunologic tests and other routine laboratory measures were often unremarkable. Common treatments that have been used for linear cutaneous lupus erythematosus include antimalarials, topical corticosteroids, oral corticosteroids, topical calcineurin inhibitors, dapsone, intralesional corticosteroids, and thalidomide. More recently, Janus kinase inhibitors like baricitinib have also been used with success. Most reviewed cases achieved least partial remission with treatment, although 10.5% of patients had no improvement and 6.6% of patients had recurrence of skin lesions after initial improvement.

---

### References

Jin H, Zhang G, Zhou Y, et al. Old lines tell new tales: Blaschko linear lupus erythematosus. *Autoimmun Rev.* 2016;15(4):291-306.

Zhan J, Chen F, Jin Y, et al. Blaschko linear lupus erythematosus treated with baricitinib: A case report. *J Dermatol.* 2023;50(7):e213-e215.

Abe M, Ishikawa O, Miyachi Y. Linear cutaneous lupus erythematosus following the lines of Blaschko. *Br J Dermatol.* 1998;139(2):307-310.

## CASE #17

### Authors

Autumn Saizan M.D.; Jun Kang M.D.  
Johns Hopkins, Department of Dermatology

### History

Our patient is a 38 yo F with a history of prior tobacco use who presented for rapidly progressive skin hardening. She first noticed painful brown spots on the back that became more diffuse. Over the course of weeks, her movement became significantly restricted due to skin tightening and swelling of the extremities. She endorsed hair loss, dry eyes/mouth, dyspnea, joint swelling, arthralgias, myalgias, and weight loss. Denied Raynaud's or dysphagia.

### Physical Examination

There was microstomia w/ generalized thickened hyperpigmented circumferential indurated plaques involving the trunk, extremities w/ an associated 10-degree flexion contracture of the R elbow, and the dorsal hands but sparing the fingers. +Groove sign noted on right arm.

### Laboratory Data

**Normal:** ANA, ENAs, Scleroderma Ab Panel (except RNP11/PMSCL75), Myositis Panel, APS Panel, ANCA, RF, C3, C4, CRP, CCP, Flow Cytometry, SPEP, IFE, Ig Panel, Kappa/Lambda Free Light Chains

**Abnormal:** Eos Abs: 1.84; RP11 Antibody, 12 (<11); PM/SCL-75 Antibody, 12 (< 11)

### Radiologic Data

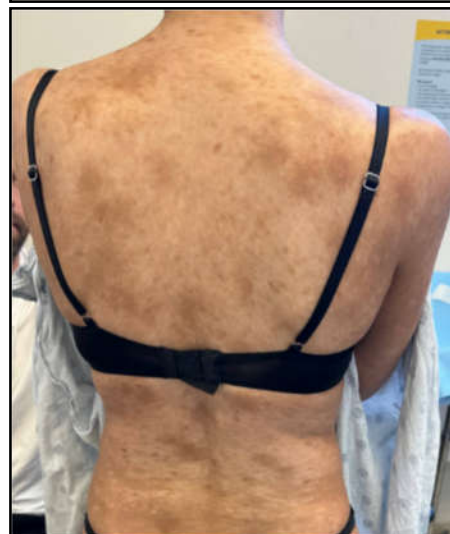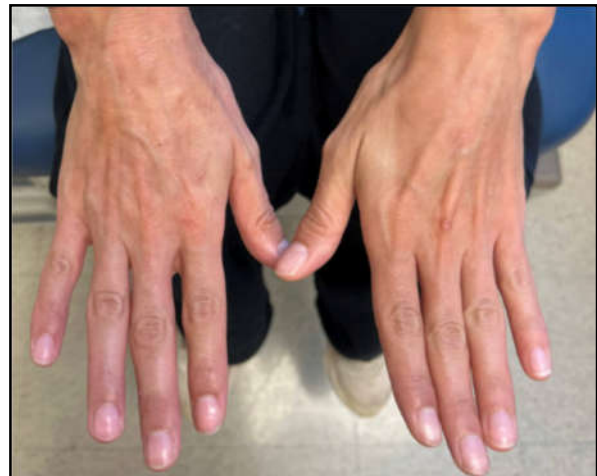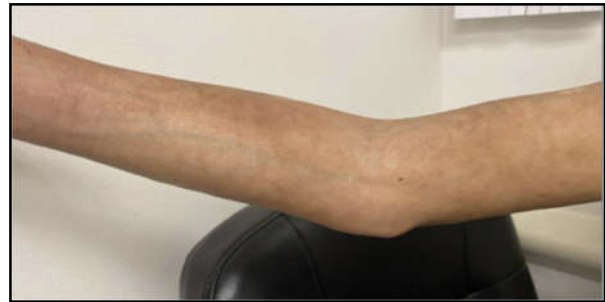(2/24 PFTs; 5/24 High Resolution CT Chest, 5/24 TTE, 9/24 EGD): Normal; (12/2024 MRI lower ext. w/wo contrast): B/L non-diffuse multifocal mild edema and enhancement involving the superficial fascia.

### Histopathology

(1/17/24, Left Lower Abdomen) The biopsy showed thickened dermal collagen w/ entrapment of adnexal structures and a deep lymphoplasmacytic infiltrate w/ scattered eosinophils c/w morphea/scleroderma.

### Treatment

Patient's prior treatments include steroids, UVA1, IVIG, MTX, MMF, and topical tofacitinib, which were ultimately discontinued due to side effects and/or lack of improvement. Patient is now on oral ruxolitinib monotherapy 20 mg BID with notable improvement.



## Treatment of Generalized Pansclerotic Morphea and Eosinophilic Fasciitis with a Janus Kinase Inhibitor

---

Morphea is a fibrosing skin condition that exists on a spectrum encompassing several phenotypes of varying severity. These subtypes range from solitary superficial indurated plaques to more diffuse circumferential thickening and hardening of the skin, often causing joint contracture and leg length discrepancy. Eosinophilic fasciitis (EF), characterized by inflammation of the fascia, is often regarded as a more severe form of morphea.

For patients with generalized morphea, it is important that systemic sclerosis (SSc) is ruled out. Histologically, morphea and SSc are identical. Physical exam along with laboratory workup and imaging, if needed, help distinguish the two, as patient's with morphea do not have sclerodactyly, dilatation of nailfold capillaries, SSc-specific antibodies, or fibrosis of internal organs.

The pathogenesis of morphea remains unclear. However, increased collagen formation in the setting of autoimmune dysfunction is the suspected underlying process. Transforming growth factor – beta1 (TGF-Beta 1) is thought to be a key driver in morphea pathogenesis as it increases fibroblast proliferation and collagen deposition and inhibits matrix degradation. With respect to EF, the pathogenesis has yet to be elucidated; however, strenuous exercise or trauma are thought to be common triggers.

Methotrexate and prednisone are common first line treatments for generalized morphea and EF; however, they are not always effective. Recently, there have been reports highlighting the utility of janus kinase inhibitors (JAKi) in the treatment of generalized deep morphea and EF as well as sclerodermatous cutaneous graft-vs-host disease. TGF-Beta 1, a key driver of fibrosis in morphea, is dependent on JAK2 and downstream activation of the JAK/STAT pathway ultimately leads to transcription of profibrotic and proinflammatory genes. Of note, a clinical trial on the use of tofacitinib for diffuse cutaneous systemic sclerosis is currently underway.

While JAKi have demonstrated efficacy in the treatment of several dermatologic conditions, it is important to be aware of their side effects, which include but are not limited to, immunosuppression, malignancy, hematologic abnormalities, liver and kidney injury, hyperlipidemia, and thromboembolism. Appropriate baseline screening and routine monitoring should be done for all patients on JAKi. Nevertheless, current studies suggest JAKi are well tolerated without adverse side effects amongst morphea and SSc patients, albeit safety data is currently limited.

---

### References

- Kim SR, Charos A, Damsky W, Heald P, Girardi M, King BA. Treatment of generalized deep morphea and eosinophilic fasciitis with the Janus kinase inhibitor tofacitinib. *JAAD Case Rep.* 2018 Apr 30;4(5):443-445.
- McGaugh S, Kallis P, De Benedetto A, Thomas RM. Janus kinase inhibitors for treatment of morphea and systemic sclerosis: A literature review. *Dermatol Ther.* 2022 Jun;35(6): e15437.
- Mertens JS, Seyger MMB, Thurlings RM, Radstake TRDJ, de Jong EMGJ. Morphea and Eosinophilic Fasciitis: An Update. *Am J Clin Dermatol.* 2017 Aug;18(4):491-512.
- Scheinberg M, Sabbagh C, Ferreira S, Michalany N. Full histological and clinical regression of morphea with tofacitinib. *Clin Rheumatol.* 2020 Sep;39(9):2827-2828.

## CASE #18

### Authors

Justin J. Choi, MD  
Department of Dermatology  
Johns Hopkins University School of Medicine

### History

Our patient is a 55-year-old female with a past medical history of hidradenitis suppurativa (HS) who presents with a one week history of a painful pustular eruption predominantly on the bilateral lower extremities. The patient had initiated adalimumab approximately seven months prior to this eruption for stage III HS, and had recently switched to secukinumab two months prior to the current eruption due to treatment failure. In the week preceding this rash, patient experienced a flare of her HS necessitating urgent evaluation by a non-dermatologic provider, who prescribed a course of amoxicillin that patient began several days cephalixin to the onset of this eruption.

### Physical Examination

Innumerable pustules and vesicles, many coalescing into larger bullae predominantly on the bilateral lower extremities and few on the trunk. Lesions in various stages of healing, with pustules/bullae admixed with open erosions and hemorrhagic crusting.

### Laboratory Data

#### (Date of study)

**Normal:** CMP, CBC, HSV/VZV, mpox qual NAT, enterovirus NAT, coxsackie AB, tissue cultures (bacterial, fungal, mycobacterial), bacterial culture, respiratory viral panel, UA w/ trace protein (no hematuria), T-spot.

**Abnormal:** ESR/CRP

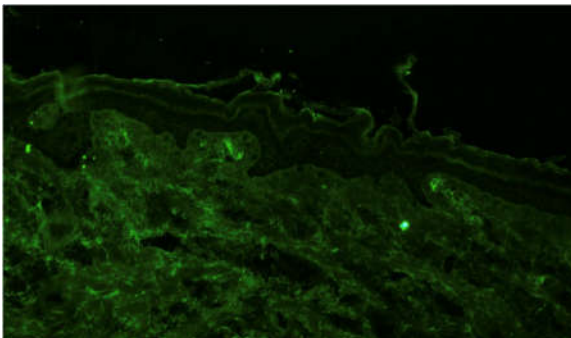
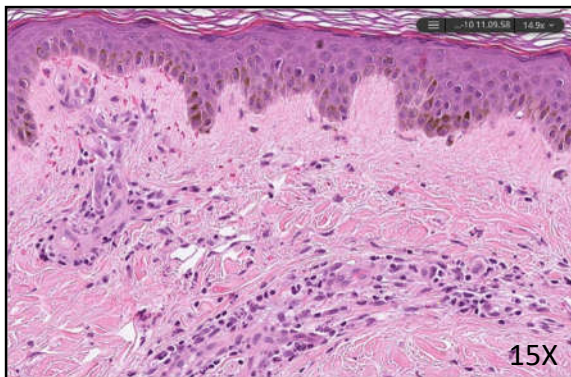
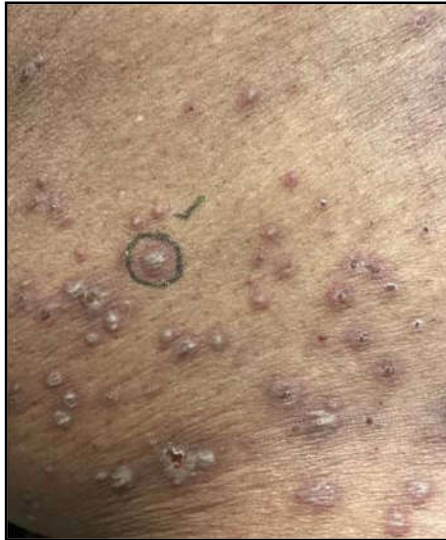### Histopathology

(H&E: 12/14/2024, left lower extremity): perivascular dermatitis with neutrophils, eosinophils, karyorrhexis, and extravasated erythrocytes.

(DIF: 12/14/2024, left lower extremity): Granular deposition of IgA in superficial dermal blood vessels. Negative IgG, IgM, C3, and fibrin.

### Treatment

Patient was initiated on a steroid taper, starting at 60 mg with a 10 mg weekly reduction. She maintains close follow-up to monitor for renal impairment with monthly labs, which have remained stable.



## Pustular IgA Vasculitis in an Adult

---

IgA vasculitis (IgAV), formerly known as Henoch–Schönlein Purpura, is a cutaneous small vessel vasculitis caused by IgA deposition in post-capillary venules. IgAV is largely observed in children, but is associated with greater mortality when seen in older patients. In children, IgAV is thought to occur following upper respiratory infections; however, a causative mechanism has yet to be defined. In adults, IgAV may be associated with medications and malignancies. Cutaneous IgAV classically presents with palpable purpura, although bullous and pustular varieties are more likely to be seen in older patients. Lesions are symmetrically distributed and favor the lower extremities. Histologically, IgAV manifests as LCV, although bullous variants that histologically mimic viral infections have been described. Direct immunofluorescence demonstrates perivascular IgA deposition. Spontaneous regression begins 10 to 14 days after onset, with resolution usually attained within months. Because of the self-limited nature of cutaneous IgAV, treatment is typically directed toward symptom management.

Extracutaneous IgAV principally affects the gastrointestinal tract, kidneys, and joints. Renal involvement remains the foremost cause of morbidity and mortality in adults; IgAV-associated glomerulonephritis occurs in 45 to 85% of adults within 6 months and may occur up to 36 months after onset. Thus, IgAV presenting in adults warrants long-term surveillance. Currently, no consensus exists regarding therapeutic strategies aimed to prevent IgA nephropathy, particularly in adults. While corticosteroids remain the mainstay of treatment, their use remains controversial given that most studies evaluating their efficacy were conducted on children and extrapolated to adults, while also failing to demonstrate a clear benefit. Thus, their role may be limited to use as treatment alongside ACE inhibitors and ARBs rather than prevention, reserved primarily for patients with severe renal disease (hypertension, baseline renal impairment, significant hematuria, and severe/persistent proteinuria). Ultimately, those with significant renal involvement necessitate a referral to nephrology and close long-term follow-up.

---

### References

- Bui IT, et al. Hemorrhagic bullous IgA vasculitis in pediatric skin of color: an mpox mimicker. *Int J Dermatol*. 2024;63(4):541-542.
- Maritati F, et al. Adult-onset IgA vasculitis (Henoch-Schönlein): Update on therapy. *Presse Med*. 2020;49(3):104035.
- Nossent J, et al. Morbidity and mortality in adult-onset IgA vasculitis: a long-term population-based cohort study. *Rheumatology (Oxford)*. 2021;61(1):291-298.
- Parums DV. A Review of IgA Vasculitis (Henoch-Schönlein Purpura) Past, Present, and Future. *Med Sci Monit*. 2024;30:e943912. Published 2024 Jan 28.



**CASE #19****Authors**

Suzanne Xu, M.D.  
Robert J Smith, M.D.  
JHH Department of Dermatology

**History**

Our patient is a 15-year old previously healthy female who presented to Pediatric Rheumatology with diffuse polyarticular arthritis and serologic markers consistent with an overlap syndrome of mixed connective tissue disease and systemic lupus erythematosus. Two months after initiation of IV methylprednisolone and IV belimumab, she developed scattered tense small vesicles and bullae along the anterior and lateral neck. Out of concern for a cutaneous adverse drug reaction, her medications were paused, and she was referred to Pediatric Dermatology. The family initially declined biopsy due to care fatigue, but after spread of the bullae to the proximal thighs and arms, the family was amenable to additional tissue work-up.

**Physical Examination**

At initial presentation, the patient's exam was notable for >20 vesicles and both hypopigmented and hyperpigmented patches of the face. At follow up visit, the patient additionally had an intact 1 cm bullae, multiple flaccid bullae, and erosions on medial thighs and hypopigmented macules at site of prior vesicles on neck. She subsequently developed diffuse tense bullae of the chest, arms, and legs.

**Laboratory Data****Abnormal:**

6/2024: positive ANA, C3 22 (L), C4 4 (L)  
8/2024: Sm IgG >310, dsDNA 1:160, RNP IgG >192, WBC 3.10 (L), Hgb 9.5 (L)

**Histopathology**

11/2024 H&E of left medial thigh:  
Subepidermal blister with neutrophils

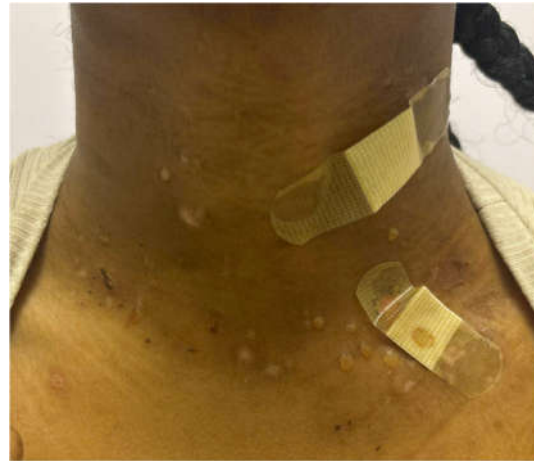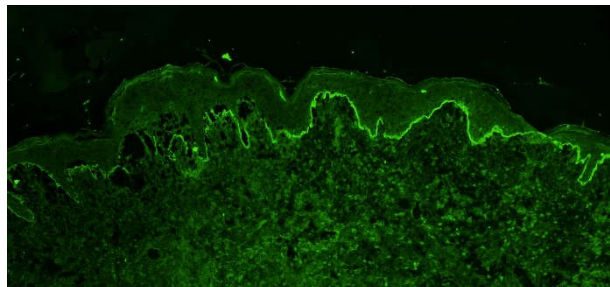
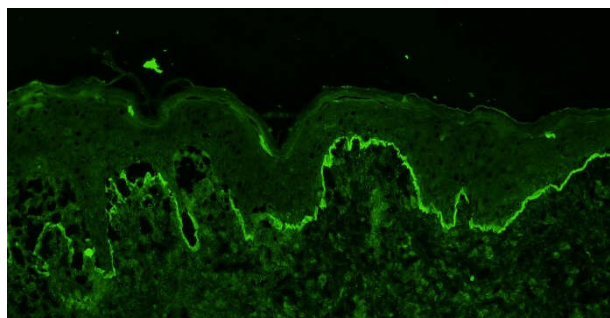
**11/2024 DIF of left medial thigh:**

There is heavy linear deposition along the basement membrane zone of IgG, IgA, IgM and C3. Negative Fibrin. In areas of

blistering, immunoreactants are present only on the floor of the blister cavity. This pattern of deposition is seen in epidermolysis bullosa acquisita, and in the context of co-existent SLE, is typical for Bullous SLE.

**Treatment**

She was resumed on IV methylprednisolone, IV belimumab, and hydroxychloroquine on 12/2024, and initiated on PO dapsone by dermatology with fewer new bullae and faster healing.

**DIF – IgG 100x****DIF – IgG 200x**

## **Bullous Systemic Lupus Erythematosus**

---

Bullous systemic lupus erythematosus (BSLE) is a rare cutaneous manifestation of systemic lupus erythematosus (SLE), presenting with a brisk subepidermal vesiculobullous eruption in a photo-predominant distribution. Bullous lupus is classified as a variant of acute cutaneous lupus erythematosus. A combined multi-center retrospective study and literature review of BSLE cases in English and French identified 128 cases involving predominantly young women with extra-cutaneous manifestations of SLE. 39% of cases were in patients with Fitzpatrick V and VI skin types and the median age was 22. Importantly, patients being evaluated for BSLE must satisfy the criteria for SLE diagnosis (either EULAR/ACR or SLICC criteria); in some cases, bullous cutaneous lupus may be the first manifestation of the patient's SLE. There is limited literature specifically on pediatric cases of BSLE. In a retrospective study of pediatric BSLE cases at a single institution in Thailand, Panombualert et al found five of 1,415 identified SLE pediatric patients had findings consistent with BSLE and that all five displayed high SLE activity at time of presentation.

BSLE is thought to be related to autoantibodies to type VII collagen, which in turn leads to complement activation and bullae formation. Epitope spreading may also lead to autoantibodies against other components of the basement membrane. The histology of BSLE is notable for neutrophils in the upper dermis, subepidermal blistering, and a perivascular inflammatory infiltrate. Large deposits of mucin may also be present. Direct immune fluorescence will show deposition of IgG, IgA, IgM, and complement components at the dermoepidermal junction, similar to EBA.

Multiple treatment modalities have been used in BSLE. In the review of 128 cases above, dapson led to improvement in 90% of the cases where it was utilized; however, its use was limited by its side effect profile including hematologic, hepatic, and renal toxicity. Other options for refractory cases include systemic corticosteroids, cyclophosphamide, azathioprine, mycophenolate, and antimalarials. IVIG, rituximab, anakinra, and methotrexate have also been reported. Patients should be counseled that while the vesicles and bullae of BSLE typically heal without scarring or milia, they may cause post-inflammatory hyper- or hypopigmentation.

---

### **References**

Contestable, J.J., Edhegard, K.D. & Meyerle, J.H. Bullous Systemic Lupus Erythematosus: A Review and Update to Diagnosis and Treatment. *Am J Clin Dermatol.* 2014; 15, 517–524.

de Risi-Pugliese T, Cohen Aubart F, Haroche J, et al. Clinical, histological, immunological presentations and outcomes of bullous systemic lupus erythematosus: 10 New cases and a literature review of 118 cases. *Semin Arthritis Rheum.* 2018; 48(1):83-89.

Duan, L., Chen, L., Zhong, S., et al. Treatment of Bullous Systemic Lupus Erythematosus. *Journal of Immunology Research.* 2015; 167064, 6 pages.

Panombualert, S., Techasatian, L., Uppala, R., et al. A Rare Manifestation of Bullous Systemic Lupus Erythematosus in Children: A 10-year Retrospective Study in a Tertiary Care Hospital, *Autoimmune Diseases*, 2022, 9388745, 6 pages.

## CASE #20

### Authors

David M. Weiner, M.D., M.B.E.  
Justin J. Choi, M.D.  
Myriam L. V. Gonzalez, M.D., M.P.H.

### History

Our patient is a thirty-one-year-old female with a history of Crohn's disease (diagnosed 2012; on adalimumab 40mg every other week) who presented to our clinic for evaluation of painful draining nodules and plaques in the groin and buttock ongoing for several years. Over the past three months, she has noticed similar lesions spreading to the inguinal folds and medial thighs.

### Physical Examination

There are well-demarcated pink and tan malodorous infiltrative plaques with draining tracts and some linear ulcers on the mons pubis, inguinal folds, and gluteal cleft.

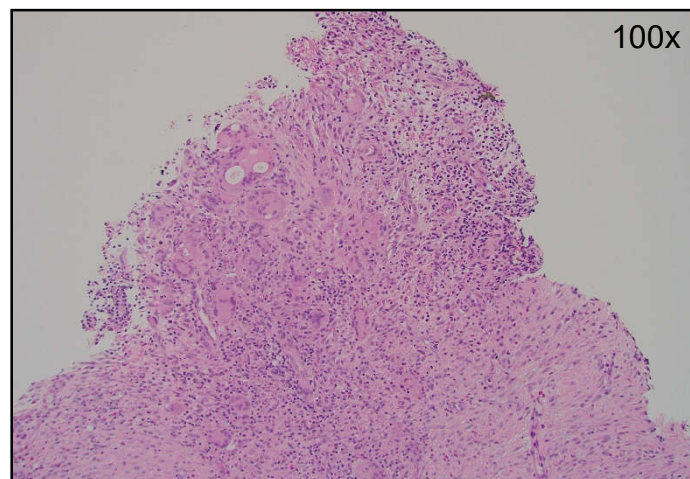
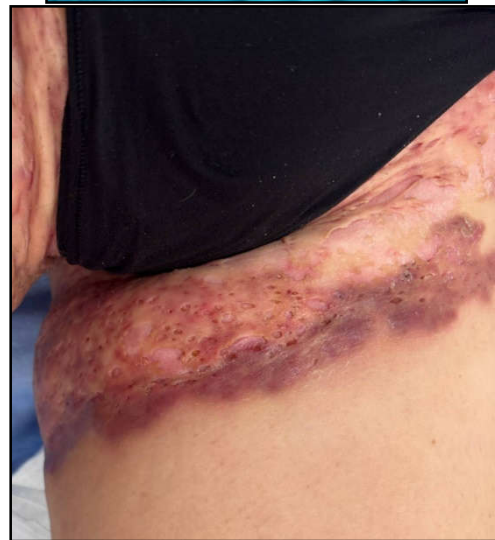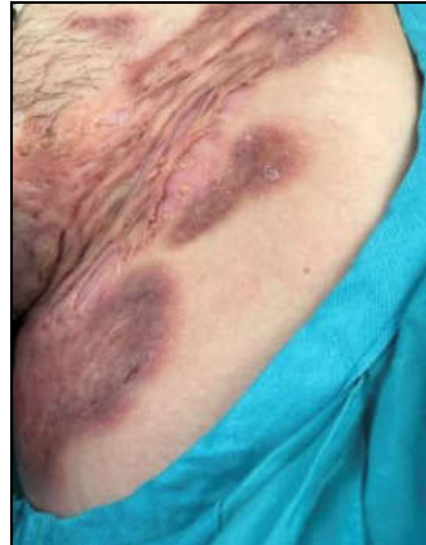### Laboratory Data: None

### Histopathology

7/10/2023, left mons pubis. The biopsy shows noncaseating granulomatous dermatitis, consistent with cutaneous Crohn's.

### Treatment

The patient has a history of Crohn's diagnosed in 2012 and refractory to infliximab, vedolizumab, azathioprine, and adalimumab. She had a subtotal colectomy and end ileostomy in 2015. After biopsy in July 2023 confirmed cutaneous Crohn's, adalimumab was increased to 80mg weekly, with adequate control of GI symptoms but not the skin. Addition of methotrexate 15mg weekly did not improve her skin. Most recently, the patient was switched to Upadacitinib in February 2023.



---

## Recalcitrant Cutaneous Crohn's

---

Cutaneous Crohn's disease is a rare manifestation of Crohn's disease involving granulomatous inflammation of the skin which can occur at sites contiguous to or, more rarely, distant from the gastrointestinal tract. This condition was first described by Parks et al. in 1965.

The clinical presentation can vary widely. Lesions may be solitary or multiple and may occur anywhere on the body but most often present on the genital and perianal regions. Non-genital involvement can present with vegetative plaques, nodules, ulcers, and/or sinus tracts. Genital involvement often presents with erythema, edema, and/or induration of the labia or penis and scrotum. Skin folds such as the inguinal folds often develop slit-like linear ulcerations. Diagnosis is confirmed through histopathological examination revealing non-caseating granulomas.

The pathogenesis is poorly understood. There are likely multifactorial immune mechanisms and genetic factors involved. It is theorized that intestinal antigens can either circulate to the skin or trigger cross-reactivity with skin antigens and result in a granulomatous response. Dysregulation of IL-23/Th17 signaling is an important mediator of Crohn's disease in general, but it is not confirmed whether the same molecular mechanisms play a role in cutaneous Crohn's.

The differential diagnosis of cutaneous Crohn's is broad. Intertriginous lesions may mimic hidradenitis suppurativa or intertrigo. Ulcerated lesions may resemble pyoderma gangrenosum. Other granulomatous conditions such as sarcoidosis and mycobacterial infections are also on the differential.

As cutaneous Crohn's is a rare disease, large-scale studies of therapeutic options are lacking. Cutaneous disease can be persistent even if the patient's intestinal disease is well-controlled. Localized lesions may be treated with topical or injected steroids or oral metronidazole. Surgical excision is an option for refractory localized disease, but recurrence is common. Management of extensive skin disease is similar to that of active intestinal disease and includes systemic medications such as sulfasalazine, corticosteroids, TNF-alpha inhibitors, IL-23 inhibitors, azathioprine, and JAK inhibitors. A recent report described the resolution of cutaneous Crohn's and improvement of intestinal symptoms with upadacitinib, an oral JAK-1 inhibitor, in a patient previously refractory to adalimumab, methotrexate, and infliximab. The cutaneous lesions improved within two months and completely resolved within four months. Another report described mild improvement of cutaneous Crohn's in a patient receiving both upadacitinib and ustekinumab.

---

### References

Agarwal, A., et al. "Off-label use of janus kinase inhibitors in inflammatory cutaneous diseases." *Journal of drugs in dermatology: JDD* 22.12 (2023): 1183-1190.

Burningham, Kevin M., et al. "Resolution of metastatic cutaneous Crohn's disease with upadacitinib monotherapy." *JAAD Case Reports* 46 (2024): 81-84.

Ickrath, F., et al. "Metastatic Crohn's disease: an underestimated entity." *JDDG: Journal der Deutschen Dermatologischen Gesellschaft* 19.7 (2021): 973-982.

Loftus Jr, E., et al. "Upadacitinib induction and maintenance therapy for Crohn's disease." *New England Journal of Medicine* 388.21 (2023): 1966-1980.

Parks, A. et al. "Crohn's disease with cutaneous involvement." *Journal of the Royal Society of Medicine* (1965): 241-242.

**CASE #21****Authors**

Sai Talluru, M.D.  
Jun Kang, M.D.  
Johns Hopkins Dermatology

**History**

Our patient is a 30-year-old Caucasian woman who presented to our clinic for evaluation of 18-month history of progressive thick scaly rash on the palms, soles, elbows, scalp and eyelids with more diffuse rash on the trunk and extremities. Endorsed pain on the palms and soles, but denied significant pruritus, weakness, joint pain, dysphagia, or weakness. She has a history of Hashimoto's thyroiditis and alopecia areata. Family history notable for mother with Hashimoto's thyroiditis and brother with alopecia areata. No other family history of autoimmune disease. No family history of psoriasis.

**Physical Examination**

There are keratotic papules and plaques on the scalp, elbows, knees, dorsal feet, and dorsal hands overlying MCP/PIP/DIPs and on the lateral aspects of digits. Palms and soles with fissuring keratotic plaques. Proximal medial thighs, ventral forearms, and posterior axillary folds with scaly dull pink plaques with follicular keratoses. Dull-pink livedoid patches on the proximal upper and lower extremities. No LAD or nail-fold changes.

**Laboratory Data****10/15/2024**

**Normal:** CBC, CMP, CK, Aldolase, LDH, ANA, Ro/La, OMRF, TCR rearrangement (tissue & blood), PFTs

**Abnormal:** IgE, 7858 (<114); CXCL 9, 1,849 (<647); Whole genome micro array testing with compound heterozygous PAD13 mutation (no known associations with skin disease)

**Radiologic Data****June 2022**

**CT Chest, Abdomen, Pelvis with Contrast:** No suspicious mass or significant adenopathy

**Histopathology**

**(7/2021, right arm):** Outside biopsy, read as second opinion at Johns Hopkins showed vacuolar interface dermatitis with intraepidermal lymphocytes.

**(1/2022, right inner thigh and left posterior axillary fold)** Biopsies show spongiotic vacuolar interface and perivascular dermatitis with intraepidermal lymphocytes. TCR-rearrangement polyclonal.

**(2/2022, left elbow)** Biopsy shows psoriasiform dermatitis with regular epidermal acanthosis, papillomatosis, and overlying hyperkeratosis characterized by alternating ortho- and parakeratosis. Mild epidermal spongiosis noted with few scattered small round intraepidermal lymphocytes. Mild follicular plugging is noted. Subtle vacuolar changes of the basal keratinocytes with inconspicuous basilar dyskeratotic keratinocytes. DIF was negative.

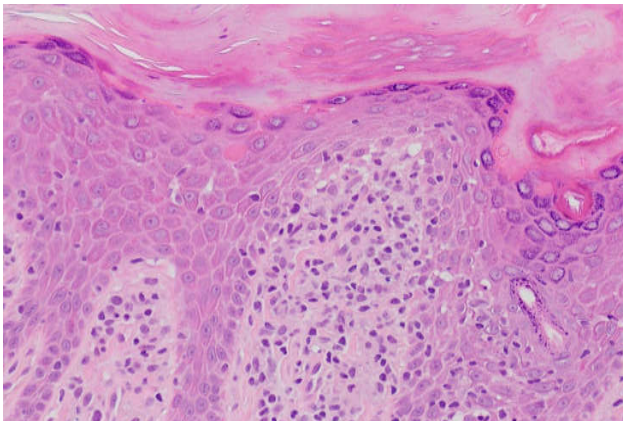
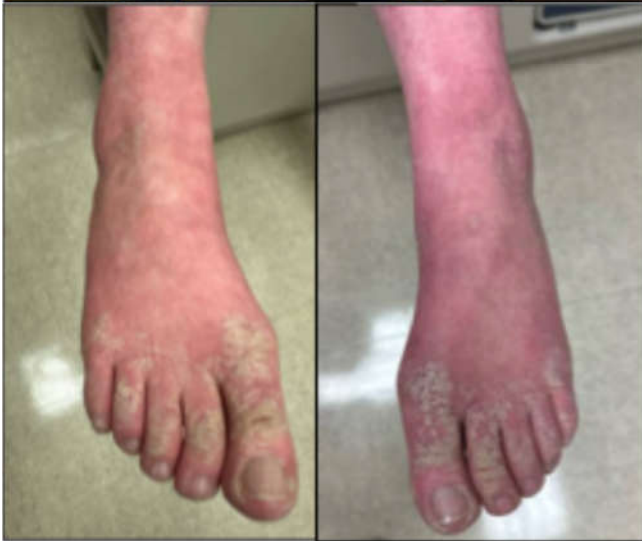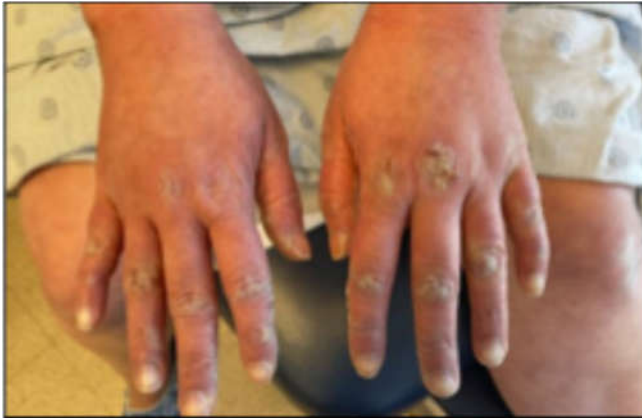**(7/2023, right dorsal elbow and lateral upper thigh)** Biopsies showed psoriasiform epidermal hyperplasia and spongiotic dermatitis with intraepidermal lymphocytes. An indeterminate was noted on right elbow specimen. The lateral thigh sample showed polyclonal TCR gene rearrangement. DIF was negative for both specimens.

**(10/15/2024, right elbow and left 4th finger dorsal PIP)** Biopsies showed vacuolar interface dermatitis with focal alternating parakeratosis and orthokeratosis in the stratum corneum and dyskeratotic keratinocytes within the epidermis. TCR gene rearrangement studies were polyclonal



### Treatment

Patient has tried multiple therapies with limited response including topical steroids, methotrexate (MTX) 20 mg/week, mofetil mycophenolate (MMF) 1 g BID, IVIG in combination with MMF, IVIG in combination with MTX, ixekizumab in combination with MTX, and deucravacitinib 6 mg daily. Recently started on ruxolitinib 10 mg twice daily in combination with topical clobetasol and triamcinolone.



## Wong Type Dermatomyositis

---

Wong-type dermatomyositis is a rare variant of dermatomyositis (DM) with less than 45 cases reported in the literature. It is an eponym for Dr. Wong who described large series of 23 patients of Asian descent with DM in *British Journal of Dermatology* in 1969. Eleven of twenty-three patients had variant with lesions resembling pityriasis rubra pilaris (PRP) with follicular, erythematous, and hyperkeratotic papules on backs of the hands and linear distribution over the bony prominences. Also reported was a distribution of these lesions along posterior neck, forehead, and scalp in some patients. Heliotrope rash and Gottron's papules have also been described in these patients. Palmar-plantar keratoderma (PPK) has been reported in only eleven patients with Wong-type DM, with two patients in the original series. A few patients with Wong-type DM also lack clinical muscular involvement. There are a few case reports describing psoriasiform papules rather than scattered papules as seen in PRP in Wong-type DM.

Histopathological findings reveal overlapping features. As in PRP, pathology usually show features of PRP with compact orthokeratosis alternating with parakeratosis in checkerboard pattern. Mucin deposition and vacuolar interface dermatitis, as in DM, are also seen. Recently, columnar dyskeratosis with nonfollicular epidermal invaginations with keratotic plugs with dyskeratotic cells have suggested as potentially characteristic for the Wong-type variant.

Overall, the characteristic features of Wong-type variant of DM are characteristic keratotic follicular papules on clinical exam, resembling PRP, supported by the pathologic features described above. There are some reports to suggest this variant may have less association with internal malignancy, but such claims are limited by the small number of cases. There remains an association of this variant of DM with myositis and interstitial lung disease. So far, there is no substantial evidence to recommend variant-specific treatments. Non-classical clinical findings such as significant hyperkeratotic follicular papules may delay the clinical diagnosis of Wong-type DM.

---

### References

- Didona, D., Juratli, H. A., Scarsella, L., et al. (2020). The polymorphous spectrum of dermatomyositis: classic features, newly described skin lesions, and rare variants. *European journal of dermatology: EJD*, 30(3), 229–242
- Kowalski, E. H., Kenney, H. M., & Richardson, C. T. (2023). Wong-type dermatomyositis with interstitial lung disease and anti-SRP and -PM/Scl antibodies treated with intravenous immunoglobulin. *JAAD case reports*, 41, 26–29
- Wong KO. Dermatomyositis: a clinical investigation of twenty-three cases in Hong Kong. *Br J Dermatol* 1969; 81: 544-547

## CASE #22

### Authors

Jaclyn Daigneault, MD  
Farah Succaria, MD  
Jun Kang, MD  
Johns Hopkins Dermatology

### History

Our patient is a 86 yo F with a history of anemia, IGG kappa monoclonal gammaglobulinopathy who presented with periorbital edema and papulo-vesicular rash involving the eyelids and face, ultimately spreading to the body, also with a history of recent contrast dye exposure.

### Physical Examination

Exam showed erythema with papules with membranous changes some with overlying yellow crust on bilateral upper and lower eyelids with marked edema, small pustules on the nasal ala, and crusted papules and vesicles on the forehead. Ophthalmology exam showed chemosis and significant mucopurulent drainage. Later she developed similar papules on the hands

### Laboratory Data

**2/17/24** Her bloodwork was consistent with leukocytosis and known anemia.  
*Negative:* monkeypox swabs, adenovirus, histoplasma, T pallidum, HSV/VZV PCR and pan tissue culture.

### Radiologic Data

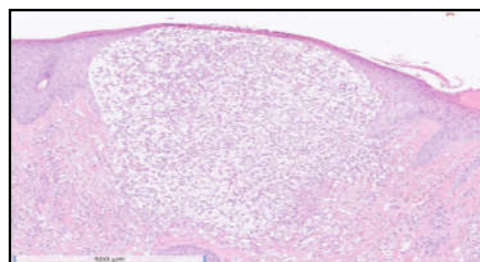
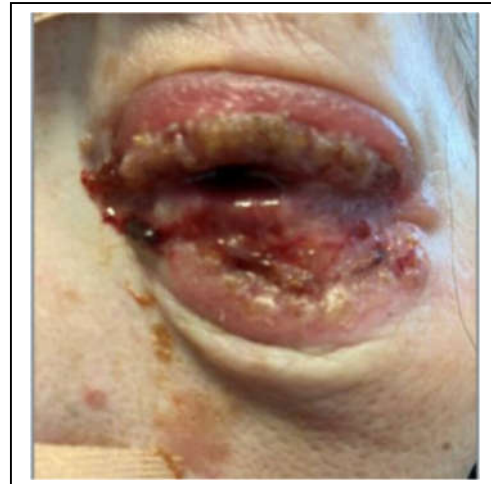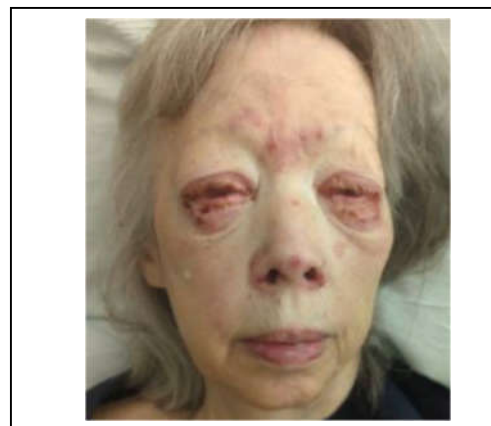
**CT face (2/17/2024)** Moderate bilateral periorbital soft tissue edema nonspecific; no obvious gas, and no post-septal involvement.

### Histopathology

**(2/18/24, Forehead)** The biopsy showed ulceration with neutrophil-rich inflammatory infiltrate and dermal edema. The histologic differential diagnosis included Sweet syndrome, other neutrophilic dermatoses, and infectious etiologies.

### Treatment

She initially received empiric Valtrex and Unasyn. Ultimately she was treated with IV methylprednisolone 1g/kg with rapid improvement in her rash. She was transitioned to oral prednisone after 3 days and discharged on a slow taper (50mg daily x 4 days, 30mg daily x 7 days, 20mg x 7 days, 10mg daily x 7 days).





## Neutrophilic Dermatoses

---

Neutrophilic dermatoses are an uncommon class of skin disorders that share the histologic feature of a dense neutrophilic infiltrate with no evidence of infection or true vasculitis. The pathogenesis is not completely understood and presentations are quite variable. Our patient with biopsy proven neutrophilic dermatosis presented with significant ocular involvement with a history of gammopathy, a known trigger for acute febrile neutrophilic dermatosis and a recent CT scan, concerning for iododerma, a rare neutrophilic dermatosis secondary to contrast media.

Acute febrile neutrophilic dermatosis, or Sweet syndrome, is an uncommon inflammatory disorder, largely manifesting on the skin, although other organ systems and symptoms may be involved, such as fever and leukocytosis. It is generally characterized by rapidly developing painful sterile, erythematous, edematous papules and plaques. Although the majority of cases are associated with benign conditions or are idiopathic, up to 30% can be associated with underlying malignancy, hematologic being the most common<sup>1</sup>. Thus, appropriate diagnosis and work-up are imperative. Treatment involves identifying the underlying trigger, i.e infection or malignancy, as well as systemic corticosteroids.

Iododerma, although not completely understood, is thought to represent a hypersensitivity reaction to systemic iodine exposure. It usually presents hours to days after exposure (up to 5 days reported in the literature)<sup>2-3</sup>. This leads to variable skin lesions including pustules, bullae, vegetating masses, and ulceration<sup>4</sup>. Treatment primarily involved discontinuation of the iodine source, however, systemic steroids can be added to help reduce systemic inflammation and symptoms.

---

### References

Callen JP. Neutrophilic dermatoses. *Dermatol Clin*. 2002 Jul;20(3):409-19. doi: 10.1016/s0733-8635(02)00006-2. PMID: 12170875.

Vegetating Iododerma With Fatal Outcome. Miranda-Romero A, Sánchez-Sambucety P, Esquivias Gómez JI, et al. *Dermatology (Basel, Switzerland)*. 1999;198(3):295-7. doi:10.1159/000018134.

Halogen Halos: Report of an Early Histopathologic Finding in Iododerma. Bitterman A, Zundell MP, Psomadakis C, et al. *Journal of Cutaneous Pathology*. 2023;50(9):806-809. doi:10.1111/cup.14489.

Alpay K, Kurkcuoglu N. Iododerma: an unusual side effect of iodide ingestion. *Pediatr Dermatol*. 1996 Jan-Feb;13(1):51-3. doi: 10.1111/j.1525-1470.1996.tb01189.x. PMID: 8919527.